

Cerebral embolic protection during transcatheter heart interventions

Victor Alfonso Jimenez Diaz^{1,2*}, MD, MPH; Samir R. Kapadia³, MD; Axel Linke⁴, MD; Darren Mylotte⁵, MD; Alexandra Lansky⁶, MD; Eberhard Grube⁷, MD; Magnus Settergren⁸, MD, PhD; Rishi Puri³, MD, PhD

1. Cardiology Department, Hospital Álvaro Cunqueiro, University Hospital of Vigo, Vigo, Spain; 2. Cardiovascular Research Group, Galicia Sur Health Research Institute (IISGS), SERGAS-UVIGO, Vigo, Spain; 3. Department of Cardiovascular Medicine, Miller Family Heart, Vascular & Thoracic Institute, Cleveland Clinic, Cleveland, OH, USA; 4. Department of Internal Medicine and Cardiology, Heart Center Dresden University Hospital, Dresden, Germany and Technische Universität Dresden, Dresden, Germany; 5. Department of Cardiology, University Hospital Galway, Galway, Ireland and University of Galway, Galway, Ireland; 6. Division of Cardiology, Yale School of Medicine, New Haven, CT, USA; 7. Department of Medicine II, Heart Center, University Hospital Bonn, Bonn, Germany; 8. Heart and Vascular Unit, Karolinska University Hospital, Stockholm, Sweden and Karolinska Institutet, Stockholm, Sweden

KEYWORDS

- aortic stenosis
- cerebral protection
- mitral valve repair
- other
- stroke
- TAVR

Abstract

Stroke remains a devastating complication of transcatheter aortic valve replacement (TAVR), with the incidence of clinically apparent stroke seemingly fixed at around 3% despite TAVR's significant evolution during the past decade. Embolic showers of debris (calcium, atheroma, valve material, foreign material) are captured in the majority of patients who have TAVR using a filter-based cerebral embolic protection device (CEPD). Additionally, in systematic brain imaging studies, the majority of patients receiving TAVR exhibit new cerebral lesions. Mechanistic studies have shown reductions in the volume of new cerebral lesions using CEPDs, yet the first randomised trial powered for periprocedural stroke within 72 hours of a transfemoral TAVR failed to meet its primary endpoint of showing superiority of the SENTINEL CEPD.

The present review summarises the clinicopathological rationale for the development of CEPDs, the evidence behind these devices to date and the emerging recognition of cerebral embolisation in many non-TAVR transcatheter procedures. Given the uniqueness of each of the various CEPDs under development, specific trials tailored to their designs will need to be undertaken to broaden the CEPD field, in addition to evaluating the role of CEPD in non-TAVR transcatheter heart interventions. Importantly, the cost-effectiveness of these devices will require assessment to broaden the adoption of CEPDs globally.

*Corresponding author: Cardiology Department, Hospital Alvaro Cunqueiro, University Hospital of Vigo, Estrada Clara Campoamor 341, 36312 Vigo, Spain. E-mail: victor.alfonso.jimenez.diaz@sergas.es

Abbreviations

AS	aortic stenosis
CEPD	cerebral embolic protection device
DW-MRI	diffusion-weighted magnetic resonance imaging
SAVR	surgical aortic valve replacement
TAVR	transcatheter aortic valve replacement
TCD	transcranial Doppler

Introduction

Current American¹ and European² valvular heart disease guidelines favour transcatheter aortic valve replacement (TAVR) via transfemoral access for patients with severe aortic stenosis (AS) across the entire surgical risk spectrum (>65 years in US guidelines, >75 years in European Union [EU] guidelines). Stroke remains a devastating complication for TAVR recipients, imparting a 6-fold higher 30-day mortality compared with those without stroke post-TAVR³⁻⁵. The burden of stroke has a substantial effect on patients, their families, health services and society in terms of morbidity and mortality along with a significant socioeconomic impact^{6,7}. Its prevention therefore represents a priority objective across all levels of healthcare in many geographies. From a patient's perspective, stroke represents the most feared complication of TAVR^{8,9}. Contemporary stroke rates related to TAVR remain at 2-4%^{3,10,11}, with no significant reduction in recent times^{3,4}. Furthermore, the detection of clinical strokes and silent cerebral lesions post-TAVR is highly dependent on the intensity of the neurological examination and imaging modality used.

Cerebral embolic protection devices (CEPD) were developed to mitigate TAVR-related stroke along with the burden of cerebral embolic debris and have been shown to be safe in various clinical settings. However, their true efficacy in stroke prevention during TAVR remains to be demonstrated. **Table 1** summarises the evidence to date of the safety and efficacy of various CEPD systems used in the TAVR population.

Aetiology and timing of strokes during TAVR

TAVR-related stroke pathogenesis is multifactorial (**Figure 1**) and can be broadly categorised into acute – linked more with the TAVR procedure *per se* – and longer-term stroke events – related more to the patient's atherosclerotic disease and overall comorbidity burden. A prior history of stroke, arterial/valvular calcium burden, bicuspid aortic valves, aortic valve pre-/postdilatation and valve-in-valve procedures have been identified as risk factors for periprocedural stroke^{3,11}, while reduced renal function, diabetes mellitus and increasing age were found to be related to the incidence of late stroke¹². Whether both periprocedural and longer-term stroke rates are directly related to the implantation procedure or the underlying type of aortic bioprosthesis (surgical vs transcatheter, intra-annular vs supra-annular transcatheter heart valves, deflectable/steerable vs non-deflectable/-steerable delivery systems) remains to be proven. This said, randomised data in lower-risk patients demonstrate lower stroke rates in TAVR versus surgical aortic valve replacement (SAVR) recipients¹³. To further

complicate matters, clinical manifestations of stroke are broad and unpredictable, ranging from major stroke with typical disabling sequelae to more subtle episodes of postprocedural transitory delirium or an acute confusional state, to clinically silent cerebral embolisation (silent brain infarction) that can only be detected on brain imaging.

Most periprocedural TAVR-related ischaemic strokes are caused by athero- or thromboembolic events provoked by the disruption of atheromatous or calcific debris arising during several procedural steps¹⁴, as summarised in **Figure 1**.

Approximately 50% of events occur during the acute periprocedural phase (~72 hrs) and in 80% of patients the stroke is detected within the first week post-TAVR^{3,10,11}. Symptoms typically appear once periprocedural anticoagulation wears off and embolised debris forms a nidus for *in situ* thrombosis.

Numerous studies have shown the presence of “silent” ischaemic brain lesions, detected by diffusion-weighted magnetic resonance imaging (DW-MRI), in almost all patients who undergo TAVR/SAVR^{15,16} (**Table 2**). Data from a systematic review and meta-analysis including 42 studies with a total of 2,632 patients showed that the incidence of new silent brain infarcts during TAVR (4.58±2.09) is greater than the incidence during SAVR (2.16±1.62), on- and off-pump coronary artery bypass graft surgeries (2.11±0.25), percutaneous coronary interventions (1.88±1.02), and mixed cardiothoracic surgeries (3.38±0.72)¹⁷. This reinforces the importance of mitigating strategies for cerebral embolisation during TAVR.

Pathological insights of TAVR-induced debris and its impact upon neurocognitive functioning

Prior studies conducted in a high surgical risk population and recent evaluations in patients at low and intermediate surgical risk have shown the presence of captured material or debris in the vast majority of patients undergoing TAVR and transcatheter mitral valve interventions when using the SENTINEL CEPD (Boston Scientific) (**Table 3**). These analyses reported significant heterogeneity of debris type captured within the filters, consisting mainly of acute thrombus, arterial wall remnants, valve tissue, calcific debris, myocardial tissue, and even foreign material. Most of the captured particles were <500 µm in size, but large particles >1,000 µm (comprising nearly 5% of all captured particles) were detected in more than 2/3 of low-risk patients. This is relevant because, while small particles are linked to silent cerebral lesions detected on DW-MRI, larger particles (>1,000 µm) may account for clinically apparent strokes. The risk for larger particle embolisation has been found to be more common in patients with bicuspid aortic valves (odds ratio [OR]: 2.91, 95% confidence interval [CI]: 1.20-7.03; p=0.02), with transcatheter heart valve repositioning being associated with a greater quantity of captured debris (OR 2.96, 95% CI: 1.42-6.16; p=0.004). Overall, the capture rate of debris, observed tissue types, and size/distribution of debris are comparable across the entire surgical risk spectrum (**Table 3**).

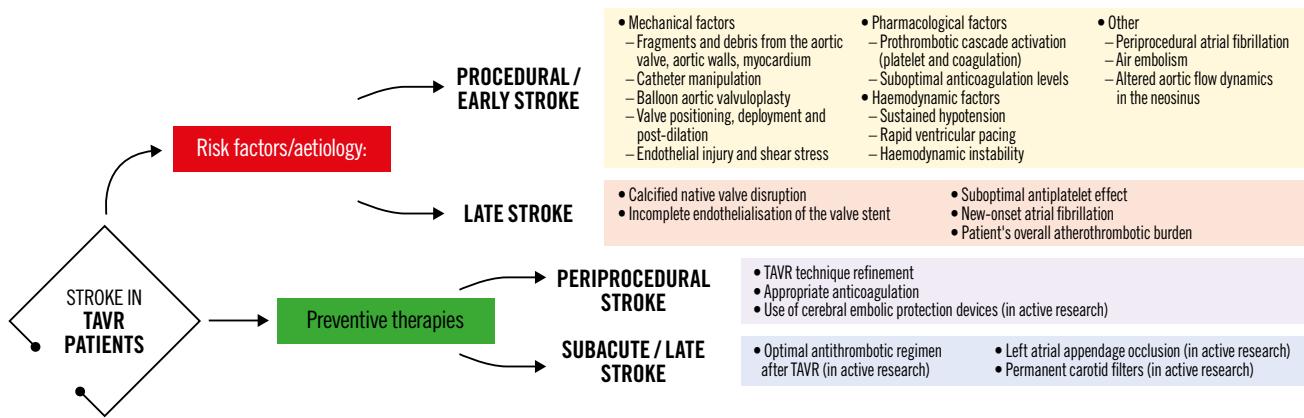


Figure 1. Potential mechanisms related to stroke during and after TAVR and preventive strategies. TAVR: transcatheter aortic valve replacement

The potential impact of silent cerebral lesions on cognitive function and its prognostic relevance at medium- to long-term follow-up is still not well defined^{18,19}. Despite the lack of overt symptoms of stroke, silent brain infarcts are associated with subtle impairments in physical function and cognitive ability that usually pass unnoticed. The presence of silent strokes in an elderly population has been thought to increase the risk of major stroke and dementia along with a faster onset of cognitive impairment²⁰. Although some reports suggest cognitive decline post-TAVR, others have reported that cognitive improvement can be achieved among TAVR recipients with pre-existing impaired cognitive function prior to the procedure, possibly related to haemodynamic improvement following resolution of aortic stenosis²¹. However, the initial data of neurocognitive tests were primarily obtained from elderly patients who had a high or prohibitive risk of surgery and a pre-existing impaired baseline neurocognitive function, which made the detection of subtle neurocognitive changes due to TAVR extremely challenging. Additionally, the population currently evaluated with neurocognitive testing remains small, the tests used to assess cognitive function are heterogeneous across studies, and clinical follow-up remains too short to be able to determine long-term impact. Conclusive data are therefore currently lacking to tie the link between cerebral embolisation and longer-term cognitive decline. However, emerging data indicate that silent brain lesions may not be benign and that their mitigation in the younger TAVR population may ultimately prove clinically relevant.

Cerebral embolic protection devices

Given the ubiquitous showering of debris during TAVR and transcatheter mitral interventions (Table 3), adjunctive use of a CEPD during transcatheter heart valve procedures to mitigate cerebral embolisation (along with its clinical consequences) seems intuitively beneficial. Stroke reduction and lessening the extent of neurological damage notionally seem to be sound clinical rationale for promoting CEPD use during TAVR. Despite the above, its use during TAVR remains infrequent. The SENTINEL device was

used in 7.1% of TAVR procedures across 551 sites in the USA between 2018 and 2019²². Although multiple patient and hospital characteristics have been associated with CEPD use, TAVR case volume seems to be the predominant factor associated with its use in the USA, rather than its eligibility for the Centers for Medicare & Medicaid Services (CMS) TAVR reimbursement or the CMS new technology add-on payment. This suggests that in the absence of definitive data for CEPD efficacy, reimbursement alone did not drive its use. In addition, the added risk burden due to use of a CEPD *per se*, such as thrombotic or vascular complications, should be considered, especially with CEPDs requiring larger-bore femoral access. Prior studies have shown the feasibility and safety of the currently available CEPDs²³⁻²⁷. Their use is associated with reductions in the number of new lesions on brain DW-MRI along with the total volume of brain injured, which may possibly reduce the risk of developing cognitive impairment or accentuating pre-existing neurological pathologies²³⁻²⁶. Yet their efficacy for clinical stroke prevention remains to be clearly demonstrated²⁸. Table 4 highlights the main aspects of an “ideal” CEPD. According to their mechanism of action, CEPDs can be primarily categorised into 2 groups: devices that capture (totally or partially) debris within the aorta before it reaches the brain, renal or peripheral arteries; or deflectors of debris from the aortic arch and its branches. The former may be positioned along the aortic arch and/or descending aorta or within the brachiocephalic trunk and/or common carotid arteries, while the latter are typically positioned along the roof of the aortic arch (Central illustration). Devices can also be classified into partial capture devices (SENTINEL), full capture devices (Emblok [Innovative Cardiovascular Solutions], Emboliner [Emboline], FLOWer [AorticLab]), primarily deflective devices (with small capture capacity) (TriGUARD 3 [Keystone Heart/Venus Medtech], ProtEmbo [Protembis], POINT-GUARD [Transverse Medical]), and deflection and capture devices (CAPTIS [Filterlex]). Figure 2 summarises the main characteristics of a range of CEPDs currently approved for clinical use and those in the preliminary clinical phase or in preclinical

Table 1. Success and complication rates of CEPDs in major TAVR studies.

Device	SENTINEL				TriGUARD	
Study name	MISTRAL-C ²⁹	CLEAN-TAVI ²³	SENTINEL ²⁶	PROTECTED TAVR ²⁷	DEFLECT III ⁴⁰	REFLECT II ²⁵
Study design	RCT	RCT	RCT	RCT	RCT	RCT
Number of patients	65 (device arm: 32; control arm: 33)	100 (device arm: 50; control arm: 50)	363 (device safety arm: 123; device imaging arm: 121; control arm: 119)	3,000 (device arm: 1,500; control arm: 1,500)	85 (device arm: 46; control arm: 39)	220 (device arm: 162 [41 roll-ins plus 121 randomised]; control arm: 58)
Device success	93.0%	92.0%	94.4%	94.4%	88.9%	71.0%
Primary endpoint	Incidence of new brain lesions 5 to 7 days after TAVR, assessed by DW-MRI	Numerical reduction in positive post-procedure DW-MRI brain lesions relative to baseline at 2 days following TAVR in potentially protected territories	1) Safety: incidence of MACCE at 30 days: all death, all strokes (disabling and non-disabling), and acute kidney injury (AKI; stage 3) according to VARC-2. 2) Efficacy: reduction in median total new lesion volume in protected territories between the device and control arms, as assessed by DW-MRI at 2 to 7 days after TAVR	Clinical stroke within 72 hours after TAVR or before discharge (whichever came first)	In-hospital procedural safety (MACCE), a composite of all-cause mortality, all stroke (disabling and non-disabling), life-threatening (or disabling) bleeding, AKI (stage 2 or 3), and major vascular complications	1) Safety at 30 days: a composite of all-cause death, stroke, life-threatening or disabling bleeding, stage 2-3 AKI, coronary artery obstruction requiring intervention, major vascular complications, and valve-related dysfunction requiring repeat procedure. 2) Efficacy: a hierarchical composite of (i) all-cause mortality or any stroke at 30 days, (ii) NIHSS worsening from baseline to 2-5 days post-procedure or MoCA worsening (decrease of 3 points or more from baseline) at 30 days, and (iii) total volume of cerebral ischaemic lesions detected by DW-MRI performed 2-5 days post-procedure
Complications						
Stroke/TIA	Device arm: 0; control arm: 2 patients within 30 days (disabling)	Device arm: 10%; control arm: 10% within 7 days (all non-disabling)	Device arm: 5.6%; control arm: 9.1% within 30 days (p=0.25)	Device arm: 2.3%; control arm: 2.9% within 72 hours (p=0.30)	Device arm: 2.2%; control arm: 5.1% within 72 hours (p=0.30)	Device arm: 6.4%; control arm: 5.3% in hospital (p=1.000)
Vascular complications	Minor: device arm 39%; control arm 41% at 30 days (p=0.904). Major: CEPD arm 0%; control arm 19% (p=NA)	1 (10%) patient in each treatment group with a life-threatening bleed	Device arm: 8.6%; control arm: 5.9% at 30 days (p=0.530). CEPD-related: 0.4%; TAVR-related: 8.2%	1 (0.1%) patient in the device arm	Device arm: 15.2%; control arm: 15.4% (p=0.85)	Device arm: 7.0%; control arm: 0% in hospital (p=0.039). CEPD-related: 1.9%; TAVR-related: 4.5%; aortic vascular injury: 1.3%

Table 1. Success and complication rates of CEPDs in major TAVR studies (cont'd).

ProtEmbo		Emblok	Emboliner	Embella	FIH CAPTIS	FLOWer	POINT-GUARD
PROTEMBO SF TRIAL (FIH) ⁴³	PROTEMBO C TRIAL ⁴²	Latib A et al ⁴¹	SafePass clinical program ⁴⁴⁻⁴⁶	PROTAVI-C Pilot Study ⁴⁶	CAPTIS ⁴⁷	Embrace / NAUTILUS FIH study ^{48,49}	CENTER FIH trial ⁵⁰
Non-RCT	Non-RCT	Non-RCT	Non-RCT	Non-RCT	Non-RCT	Non-RCT	Non-RCT
4	41 (37 intention-to-treat cohort, of which 31 per-protocol cohort)	20	63 (series of 3 single-arm feasibility studies: SafePass FIH: 13; SafePass 2: 31; SafePass 3: 19)	52 (device arm: 41; control arm: 11)	20 (data available for 11 patients)	75	4
100%	94.6%	100%	100%	100%	100%	100%	100%
Feasibility and safety	1) Safety: MACCE at 30 days, defined as a composite of all-cause mortality, all stroke, life-threatening or disabling bleeding, major vascular complications in the access vessels or aorta, or AKI (stage 2 or 3), all according to VARC-2. 2) Performance: rate of technical success, defined as the ability to safely deliver, deploy, and remove the device; the ability to secure and stabilise the position of the device throughout the procedure; and to deflect embolic material, defined by coverage of the 3 cerebral vessels without impeding blood flow	1) Technical success, defined as the successful insertion, placement, and removal of the Emblok device, and device performance was evaluated during and after completion of the TAVR index procedure. 2) Immediate cerebral embolic burden after TAVR, defined as the number and volume of new brain lesions as detected with DW-MRI at days 2-5 post-TAVR compared with baseline	1) Safety: incidence of 30-day MACCE (death, stroke, and stage 3 AKI) compared with a 12% historical performance goal. 2) Performance: the ability to successfully deploy and retrieve the device	Feasibility, safety, and exploratory efficacy	Safety: incidence of mortality or cerebrovascular event at 72 hours and device-related complications	1) Safety: incidence of 30-day MACCE (death, stroke, and stage 3 AKI) compared with a 14.3% historical performance goal. 2) Performance: technical success and system usability; debris captured and histopathological evaluation. 3) Clinical benefit: brain imaging (DW-MRI) at baseline and within 2-5 days after TAVR; neurocognitive protection assessed by NIHSS, MOCA and mRS at baseline, 2-7 days and 30 days after TAVR	Safety and performance
0% at 30 days	1 (2.7%) patient (CEPD retrieved prematurely because of interaction with the TAVR catheter)	0% at 30 days	2 (6.5%) patients (at day 1 and at day 17 post-TAVR) in SafePass 2, and 1 (5.2%) patient in SafePass 3 (still to be adjudicated)	2 strokes and 1 TIA in the device arm	0% at 30 days	3 (5.2%) strokes at 30 days (data from 58 patients)	Not reported
0% at 30 days	8.1% (3/37): 2 haematomas and 1 dissection treated with balloon inflation	1 (5.0%) patient at site of valve insertion	1 patient with a minor oozing at the device access site in SafePass 2	Device arm: 5 (12.2%); control arm: 1 (9.1%) (p≥0.999), at 30 days	1 (5.0%)	Not reported	Not reported

AKI: acute kidney injury; CEPD: cerebral embolic protection device; DW-MRI: diffusion-weighted magnetic resonance imaging; FIH: first-in-human; MACCE: major adverse cardiac and cerebrovascular events; MoCA: Montreal Cognitive Assessment; mRS: Modified Rankin Scale; NA: not applicable; NIHSS: National Institutes of Health Stroke Scale; RCT: randomised controlled trial; TAVR: transcatheter aortic valve replacement; TIA: transient ischaemic attack; VARC-2: Valve Academic Research Consortium-2

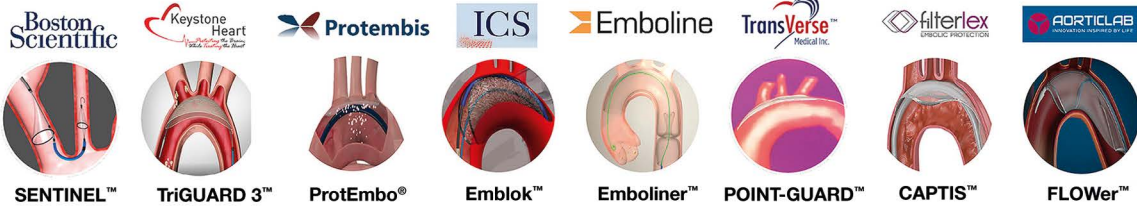
Table 2. Brain MRI results and cognitive outcomes of CEPDs in major TAVR studies.

	SENTINEL				TriGUARD	
	MISTRAL-C ²⁹	CLEAN-TAVI ²³	SENTINEL ²⁶	PROTECTED TAVR ³⁷	DEFLECT III ⁴⁰	REFLECT II ²⁵
Brain DW-MRI results	New brain lesions at 5-7 days: 78% (73% vs 87%; p=0.31). Median total new lesion volume: 95 mm ³ (10-257) vs 197 mm ³ (95-525) (p=0.17). Median total lesion volume in protected areas: 0 mm ³ (0-102) vs 76 mm ³ (40-221) (p=0.057). Absence of new lesions: 13% vs 27% (p=0.31)	New brain lesions at 2 days: 98%. Median new lesion number: 4 (3.3-7.25) vs 10 (6.75-17.00) (p<0.001). Median total new lesion volume: 242 mm ³ (159-353) vs 527 mm ³ (364-830) (p=0.001)	Median total new lesion volume at 2-7 days: device arm: 102 mm ³ ; control arm: 177 mm ³ (p=0.33)	Not performed	New brain lesions at 30 days: 80.8%; device arm: 73.1%; control arm: 88.5% (per-treatment analysis)	Median total new lesion volume at 2-5 days: device arm: 215.39 mm ³ ; control arm: 188.09 mm ³ (p=0.405)
New neurocognitive deficit	Device arm: 4%; control arm: 27% (p=0.017)	No differences between both groups regarding NIHSS, mRS and moCA at 2, 7, and 30 days	No difference in overall composite scores at baseline, 30 days, or 90 days between device and control arms	No differences between both groups in NIHSS, mRS, MoCA and CAM-ICU scores	Worsening in NIHSS score from baseline with DW-MRI evidence of ischaemia: device arm 3.1%; control arm 15.4% (p=0.160)	No differences in NIHSS score worsening at discharge (14.1 vs 7.6, p=0.18) nor at 30 days post-procedure (7.8 vs 3.6; p=0.31), in the device vs control arm, respectively
Other findings	Baseline brain MRI assessment confirmed ischaemic lesions in 11% of patients. Total lesion volume was greater in patients with self-expanding TAVR vs balloon-expandable TAVR (693 mm ³ vs 266 mm ³ ; p=0.067). In particular, the lesion volume in the posterior lobes was significantly greater with self-expanding THVs (405 mm ³ vs 92 mm ³ ; p=0.037)	The median number of periprocedural HITS was 3,196 (IQR 2,522-4,010) in the filter group and 3,674 (IQR, 2,551-5,217) in the control group	MACCE at 30 days: device arm: 7.3%; control arm: 9.9% (p=0.25). The change in neurocognitive scores from baseline to 30-day follow-up correlated with the median new lesion volume in protected territories and all territories	Disabling stroke: device arm: 0.5%; control arm: 1.3% (p=0.02) -Non-disabling stroke: device arm: 1.7%; control arm: 1.5% (p=0.67) -Acute kidney injury: device arm: 0.5%; control arm: 0.5% -NNT for prevention of disabling stroke =125	In-hospital MACCE (all-cause mortality, all stroke, life-threatening/disabling bleeding, acute kidney injury [stage 2 or 3]): device arm: 21.7%; control arm: 30.8% (p=0.34). New post-TAVR ischaemic lesions at 30-day follow-up DW-MRI were detected in 11.5% of device arm and 9.1% of control subjects (both mean single and maximum lesion volumes were 5.2±17.9 vs 3.3±11.9 mm ³ ; p=0.78). All subjects undergoing TAVR with or without TriGUARD device showed DW-MRI ischaemic lesions when the CoreValve prosthesis was used	Primary safety endpoint at 30 days (all-cause mortality, all stroke, life-threatening/disabling bleeding, coronary artery obstruction requiring intervention, acute kidney injury [stage 2 or 3], major vascular complications, valve-related dysfunction requiring intervention): device arm: 15.9%; control arm: 34.4% (p=0.0001). Primary efficacy endpoint at 30 days (all-cause mortality, all stroke, NIHSS worsening, absence of DW-MRI lesions post-procedure, total volume of cerebral lesions by DW-MRI): device arm: 45.7%; control arm: 54.3% (p=0.857)

Table 2. Brain MRI results and cognitive outcomes of CEPDs in major TAVR studies (cont'd).

ProtEmbo		Emblok	Emboliner	Embrella	FIH CAPTIS	FLOWer	POINT-GUARD
PROTEMBO SF TRIAL (FIH) ⁴³	PROTEMBO C TRIAL ⁴²	Latib A et al ⁴¹	SafePass clinical program ⁴⁴⁻⁴⁶	PROTAVI-C Pilot Study ⁴⁶	CAPTIS ⁴⁷	Embrace / Nautilus FIH study ^{48,49}	CENTER FIH trial ⁵⁰
50% reduction in number of new lesions compared to historical cohort, and 87% reduction of new lesions for the protected vs unprotected TAVR at 3 and 30 days	Median number of new lesions at 2-7 days: 8 (IQR 3-16). Median total new lesion volume: 210 mm ³ (137-456 mm ³). Average new lesion volume: 34 mm ³ (24-45 mm ³). Freedom from brain lesions >150 mm ³ : 87%. Freedom from brain lesions >350 mm ³ : 97%	New brain lesions at 2-5 days: 95%. Median number of new lesions: 10 (4.75-15.25). Median total new lesion volume: 199.9 mm ³ (83.9-447.5). Mean new lesion volume per lesion: 42.5 mm ³ (21.5-75.6)	Not performed	New brain lesions at 7 days: device arm: 100%; control arm: 100%. Median number of new lesions: device arm: 7.5 (3-13); control arm: 4 (2-8) (p=0.413). Median total new lesion volume: device arm: 305 mm ³ ; control arm: 180 mm ³ (p=0.909). Median lesion volume: device arm: 30mm ³ (20-50 mm ³); control arm: 50 mm ³ (30-70 mm ³) (p=0.003). Lesion location	Not performed	Median total new lesion volume at 2-5 days: device arm: around 500 mm ³ (32 patients); control arm: around 1,450 mm ³ (4 patients)	Pre- and post-procedure DW-MRIs were conducted, no results reported
No differences in MoCA at 30-day follow-up	No significant worsening of NIHSS in any of the patients at 30-day follow-up	0% at 30 days (NIHSS)	Not reported	No differences in the median scores (NIHSS scale, the modified Rankin Scale and the Barthel Index) compared with baseline examination (p>0.15)	No increase of NIHSS score at follow-up. 1/11 patients had an increase in mRS score at 72h and 2/10 patients at 30 days	Not reported	Not reported
All three side branch vessels of the aortic arch were covered in all patients. Minimal to no interaction with TAVR catheters was reported.	MACCE at 30 days (all-cause mortality, all stroke, life-threatening/disabling bleeding, acute kidney injury (stage 2 or 3). The largest single lesion volume detected in any of the patients was 402 mm ³ . Dwell time of the device: 30.2±13.4 min (IQR: 16 to 69) Average time for device deployment: 4.5±4.9 min	No MACCE was observed at 30 days. Debris captured in 90% of cases. Patients with full protection showed significant lower new lesion volume compared to patients without full protection (median 176.1 mm ³ [IQR 60.7 to 90.6 mm ³] vs 519.7 mm ³ [IQR 400.1 to 459.9 mm ³]; p= 0.0402 (<i>post hoc</i> analysis). No difference in terms of reduction of new lesions was seen (8.0 [IQR 4.5 to 15.0] vs 13.0 [IQR 3.0 to 15.0], respectively; p=0.179). 19 (95%) patients had new ischaemic defects at postprocedural DW-MRI. Median number of new lesions per patient: 10.00 (IQR 4.75 to 15.25), total new lesion volume: 199.9 mm ³ (IQR 83.9 to 447.5 mm ³), mean lesion volume per lesion: 42.5 mm ³ (IQR 21.5 to 75.6 mm ³). Dwell time of the device: 24.0 mins (IQR 19.2 to 27.7) Median time for device deployment: 2.0 mins (IQR 0.0 to 6.75)	MACCE at 30 days (death, stroke, and stage 3 acute kidney injury): 2 (6.5%) patients. Debris captured in 100% of cases. Average ~280 particles ≥150 µm and 2,151 particles ≥60 µm captured per patient. 66% of patients had at least 1 particle ≥1 mm size (data from SafePass 2 trial). Average 287 particles ≥150 µm and 3,175 particles ≥60 µm captured (partial and preliminary results from the SafePass 3 trial, pending final adjudication)	There was 1 radial thrombosis with no clinical consequences and 1 pseudoaneurysm of the brachial artery that required surgical repair. At 30 days, the reported incidence of life-threatening bleeding, renal insufficiency/failure, and mortality occurred in 3 patients (7.3%) for each event (p>0.999). Total number of HITS during the procedure: device arm: 632; control arm: 279 (p<0.001). Median time for device deployment: 2 min (IQR 1 to 3)	No MACCE (all-cause mortality, all TIA and stroke) was observed at 30 days. Acute kidney injury at 72 hours (or discharge): 1 (5.0%). Debris was collected in all cases, with an average total number of collected particles of 1,448, with 112 particles ≥150 µm in size, 95 particles of 150-500 µm, 11 particles of 500-1,000 µm, and 6 particles of >1,000 µm. Median deployment and retrieval time of 8 and 4 minutes, respectively	Debris collected in all cases, with an average total number of collected particles of 420 per patient, with around two-thirds being particles ≤150 µm in size (data from 15 patients)	All 4 filters showed evidence of debris capture. 4 non-device-related adverse events were reported

CAM-ICU: Confusion Assessment Method for Intensive Care Unit Patients; CEPD: cerebral embolic protection device; DW-MRI: diffusion-weighted magnetic resonance imaging; HITS: high-intensity transient signals; IQR: interquartile range; MACCE: major adverse cardiac and cerebrovascular events; MRI: magnetic resonance imaging; mRS: modified Rankin Scale; MoCA: Montreal Cognitive Assessment; NIHSS: National Institutes of Health Stroke Scale; NNT: number needed to treat; TAVR: transcatheter aortic valve replacement; THV: transcatheter heart valve; TIA: transient ischaemic attack; VARC-2: Valve Academic Research Consortium-2



	SENTINEL™	TriGUARD 3™	ProtEmbo®	Emblok™	Emboliner™	POINT-GUARD™	CAPTIS™	FLOWer™
Regulatory status	CE FDA	CE	SIH	SIH	SIH	SIH	FIH	FIH
Cerebral embolic protection	Partial	Complete	Complete	Complete	Complete	Complete	Complete	Complete
Concept	Partial capture	Deflect	Deflect	Capture and removal	Capture and removal	Deflect	Capture and removal	Capture and removal
Pore size	140 µm	115x145 µm	60 µm	125 µm	150 µm	105 µm	115x145 µm	70 µm
Vascular access	Right radial	Femoral	Left radial	Femoral (contralateral)	Femoral (contralateral)	Femoral (contralateral)	Femoral (ipsilateral)	Femoral (contralateral)
Access size	6 Fr	8 Fr	6 Fr	11 Fr	10 Fr	10 Fr	16 Fr	12 Fr
Heparin coating	No	Yes	Yes	No	Yes	No	No data	No data

Figure 2. Cerebral embolic protection devices: main features and regulatory status. CE: European conformity; Fr: French; FDA: U.S. Food and Drug Administration; FIH: first-in-human; SIH: second-in-human

development. Currently, there are 4 devices with published data in peer-reviewed journals, two of which are in clinical use, and several others remain under active investigation in early phase studies for their potential applications in TAVR and structural heart interventions (**Central illustration**).

What is the evidence for using specific CEPDs during TAVR?

THE SENTINEL CEREBRAL PROTECTION SYSTEM

The SENTINEL Cerebral Protection System consists of 2 polyurethane filters with 140 µm diameter pores fixed in a flexible nitinol radiopaque frame, advanced from a 6 Fr sheath through the right radial or right brachial artery and deployed into the ostia of brachiocephalic trunk and left common carotid artery^{23,29}. It is designed to capture emboli passing into the cerebral circulation in 2 of the 3 branches of the aortic arch. The proximal filter is aimed to be positioned at the ostium of the brachiocephalic trunk, whereas the distal filter is placed in the left common carotid, but leaving the left subclavian open, and the left vertebral circulation is unprotected^{23,29}. The device has a CE (European conformity) mark and U.S. Food and Drug Administration (FDA) approval for use within vessels measuring 9-15 mm in diameter and is, to date, the most widely used CEPD in TAVR.

The MISTRAL-C²⁹ (n=65 patients) and the CLEAN-TAVI (n=100 patients) randomised trials²³ showed fewer new lesions and smaller total lesion volumes in the SENTINEL-protected group. Neurocognitive deterioration was more frequent in the patients treated without protection.

The US SENTINEL IDE Study²⁶ was a larger multicentre study (n=363 patients) with a 1:1:1 randomisation into a safety device arm (n=123), an imaging device arm (n=121), and an imaging control arm (n=119). The authors reported debris in 99%

of the filters. Despite a numerical reduction in all-cause stroke at 30 days, statistical significance was not met (5.6% for the SENTINEL group vs 9.1% in the control group; p=0.25). Also, the median total new lesion volume in protected territories evaluated by DW-MRI 2-7 days post-TAVR did not differ significantly between the control and the CEPD groups. The CEPD group demonstrated a reduction in stroke within 72 hrs after TAVR (classified as procedural stroke by the Neurologic Academic Research Consortium [NeuroARC] definitions)³⁰ when compared to the unprotected group (3.0% vs 8.2%; p=0.053). Although the topline results of this trial failed to demonstrate a statistically significant clinical reduction in stroke events and new lesion volume, several caveats of the trial warrant consideration. Baseline abnormal brain signal volume (indicative of prior stroke) is known to impact new lesion volume assessment³¹; additionally, there is a dynamic fluctuation of T2-weighted-Fluid-Attenuated Inversion Recovery (T2/FLAIR) lesion volume from day 2 post-TAVR to day 7 post-TAVR. With this in mind, reanalysing new lesion volume in protected and unprotected brain regions when controlling for baseline cerebral infarction volume did show a protective effect of the SENTINEL CEPD in both protected (p=0.025) and unprotected territories (p=0.05)²⁶. Despite the above, the results of this *post hoc* analysis can be considered only as hypothesis-generating. The loss of brain MRI follow-up in 25% of cases was also a significant confounder for result interpretation. Moreover, the SENTINEL IDE Study was never powered to show a significant difference in clinical indices.

Three large-scale non-randomised retrospective studies from Medicare, Transcatheter Valve Therapy (TVT) and National Inpatient Sample (NIS) registry data analysed the outcomes of TAVR patients and CEPD use, with the SENTINEL CEPD, in real-world practice^{28,32,33}. There was a lack of concordance amongst

Table 3. Summary of studies using CEPDs reporting histopathological analysis.

Study	Device	N	Valve type	Percentage of patients with particles captured	Histopathological analysis/other clinical findings
AORTIC PROCEDURES					
Van Mieghem et al ⁸⁷ Circulation. (2013)	SENTINEL	40	CoreValve: 36 (90%), SAPIEN: 4 (10%)	75%	<ul style="list-style-type: none"> The captured material varied in size between 0.15 mm and 4.00 mm. Amorphous calcified material of 0.55–1.80 mm diameter (5/30, 17%) consisted of degenerative and calcified aortic valve leaflets. Collagenous and proteoglycan matrix with elastic tissue, the longest segment of 0.25–4.00 mm, (8/30, 27%) consisting in endothelial cells of the aortic surface above the calcified area. Pure collagenous material without any blood clot (4/30, 13%). Thrombotic material consisting of platelets, fibrin, and erythrocytes, with and without neutrophils of 0.15 to 2.00 mm (21/30, 70%). Of those, 13 (62%) were acute thrombi and 8 (38%) were chronic thrombi (organising thrombus). Foreign body material consisting of polymer used in catheters during TAVR (4/30, 13.3%). Two (5%) cerebrovascular events were reported (1 major stroke in the left occipital cerebral lobe and 1 TIA).
Van Mieghem et al ⁸⁸ JACC Sentinel Cardiovasc Interv. (2015)	SENTINEL	81	CoreValve: 56 (69%), SAPIEN XT: 24 (30%), Other: 1 (1%)	86%	<ul style="list-style-type: none"> The median size of debris was 1 mm (IQR 0.6 to 1.5 mm) and varied between 0.1 mm and 9.0 mm. Fibrin and thrombotic material of 0.2 to 6.2 mm (60/81, 74%). Tissue-derived debris (51/81, 63%). Degenerative aortic valve leaflets of 0.2 to 5.5 mm consisting in amorphous calcified material and collagenous and proteoglycan matrix with elastic tissue surrounded by endothelial cells (27/81, 33%). Collagenous tissue of 0.2 to 1.5 mm of undetermined origin (either vessel wall or aortic valve leaflet) (14/81, 17%). Endothelium strands of size 0.2 to 9 mm (39/81, 48%). Myocardial tissue of 0.1 to 1.7 mm (13/81, 16%). Small foreign body polymer material (8/81, 10%). Captured tissue fragments were less frequent with CoreValve than SAPIEN XT (56% vs 79%, p=0.05). There were no differences between patients with versus without captured debris regarding pre- and post-dilatation or access route (TAVTFS). The type of transcatheter valve used and valve oversizing were found as predictors of tissue embolisation (multivariate analyses). Two strokes after TAVR and one TIA with concomitant new onset atrial fibrillation were reported.
Schmidt et al ⁸⁹ J Am Heart Assoc. (2016)	SENTINEL	161	SAPIEN 3: 86 (53%), SAPIEN/SAPIEN XT: 28 (17%), CoreValve/Evolut R: 20 (12%), Lotus: 8 (5%), Direct Flow Medical system: 8 (5%), Portico: 7 (4%), JenaValve: 3 (2%), Centara: 1 (1%)	97%	<ul style="list-style-type: none"> The most common captured debris in either the proximal or distal filter were thrombi (147/161, 91%), arterial wall (109/161, 68%), valve tissue (85/161, 53%), calcification (74/161, 46%), and foreign material (49/161, 30%). Distribution of debris by filter location was not different. Patients with aortic valve predilatation more commonly showed valve tissue captured (in either or both filters) compared with patients without predilatation (67% vs 43%, p=0.0294). Valve tissue was found to be significantly increased in either or both filters in procedures with pre- and/or post-dilatation (64% vs 41%, p=0.0313). A trend towards more valve tissue captured was found in female versus male patients (63% vs 43%, p=0.0688), with more valve tissue in the distal filter in female patients (51% vs 28%, p=0.0304). Female sex (p=0.0287) and diabetes mellitus (p=0.0116) were predictive of higher rates of debris in the filters. Two (1%) cerebrovascular events were reported: 1 stroke at day 1 after TAVR (the filter of the left carotid artery was reported with malposition) and 1 TIA on day 3 after TAVR in a patient who developed new onset atrial fibrillation.
Mieghem et al ⁹⁰ EuroIntervention (2016)	SENTINEL	65 (SENTINEL use: 32)	SAPIEN 3: 35 (54%), CoreValve: 16 (25%), SAPIEN XT: 10 (15%), Others: 4 (5%)	100%	<ul style="list-style-type: none"> The captured debris consisted of fibrin thrombus (26/30, 87%), endothelium (25/30, 83%), collagenous (11/30, 37%), valve tissue (10/30, 33%), myocardium (10/30, 33%), foreign body (9/30, 30%), amorphous calcium (8/30, 27%). New brain lesions were found in 78% of patients at 5 days on follow-up MRI. The CEPD group had numerically fewer new lesions and a smaller total lesion volume (95 mm³ [IQR 10–257] vs 197 mm³ [95–525]). Patients with self-expanding valves had greater total lesion volume (63 mm³ [IQR 459–744]) compared to those with balloon-expandable valves (266 mm³ [IQR 155–358]; p=0.067). In addition, the posterior lobes of patients with self-expanding valves showed higher lesion volume (405 mm³ [IQR 332–530] vs 92 mm³ [IQR 40–240]; p=0.037). Overall, there were more patients in the CEPD group with no new lesions (27% vs 13%, p=0.31), and less patients with ten or more new brain lesions (20% vs 0%; p=0.03) and with neurocognitive deterioration (4% vs 27%, p=0.017). Two (7%) strokes at 30 days after TAVR were reported, both in the control (no device) arm.

Table 3. Summary of studies using CEPDs reporting histopathological analysis (cont'd).

Study	Device	N	Valve type	Percentage of patients with particles captured	Histopathological analysis/other clinical findings
AORTIC PROCEDURES					
Van Gils et al ⁸³ Catheter Cardiovascular Interv. (2017)	SENTINEL and Wirion carotid filter (Cardiovascular Systems, Inc)	11	Lotus: 8 (72%), SAPIEN 3: 2 (18%), CoreValve: 1 (9%)	100% in all filters	<ul style="list-style-type: none"> • Three-vessel protection was accomplished by using the SENTINEL and Wirion filters. • All filters captured debris. • Fibrin/thrombus in 100% of filters, endothelium (SENTINEL 9/11 patients vs Wirion 7/9 patients), foreign body material consisted of blue gel or coloured fibres, likely derived from catheters or the TAVR delivery system (SENTINEL 6/11 patients vs Wirion 6/9 patients). • No differences were observed between the SENTINEL and Wirion filter for any type of debris/tissue captured. • Captured debris size, counts, and types were similar between SENTINEL and Wirion filters. • 2/11 patients didn't receive the Wirion filter: in 1 patient selective cannulation of the left vertebral artery was not possible because of anatomical difficulties and in 1 patient a dissection of the left vertebral artery developed (sealed with a stent). • One patient had an ischaemic stroke 8 days after TAVR.
Kapadia et al ¹⁰⁰ JACC (2017)	SENTINEL	363 (225 with SENTINEL)	Lotus: 8 (72%), SAPIEN XT: 2 (17.8%), SAPIEN 3: 2 (52.4%), CoreValve: 1 (3.9%), Evolut R: (25.9%)	100% in all filters	<ul style="list-style-type: none"> • The captured debris consisted of acute thrombus (99%), arterial wall (94%), valve tissue (50%), calcification (50%), foreign body (36%), myocardium (16%), and organising thrombus (6%). • More than 80% of debris was 150 to 500 µm in maximum diameter; <5% was >1,000 µm. • After variables adjustment, there was a significant difference in new lesion volume favouring neuroprotection in both protected territories (p=0.025) and unprotected territories (p=0.050).
Schmidt et al ¹⁰¹ JACC Cardiovasc Interv. (2018)	SENTINEL	246	SAPIEN 3: 145 (59%), Evolut R: 40 (16%), Lotus: 36 (15%), SAPIEN XT: 25 (10%)	99%	<ul style="list-style-type: none"> • The captured debris consisted of acute thrombus (~95%), arterial wall (~85%), valve tissue (~55%), calcification (~55%), foreign body (~45%), organising thrombus (~15%), myocardium (~15%), and necrotic core (~3%). • 90% of all patients had large particles (≥500 µm), and 53% had particles ≥1 mm. • Patients treated with an Evolut R or a Lotus valve had larger particles (≥1,000 µm) and greater total captured particle area compared to those treated with a SAPIEN 3 or SAPIEN XT valve. • Transcatheter valve type was the only significant contributor to the morphometric results (multivariate analysis).
Seeger et al ¹⁰² JACC Cardiovasc Interv. (2018)	SENTINEL	100	SAPIEN 3: 42 (42%), Evolut R: 35 (35%), Lotus: 23 (23%)	99%	<ul style="list-style-type: none"> • The captured debris consisted of acute platelet-rich thrombus (99%), arterial wall (84%), valve tissue (84%), calcification (58%), foreign body (33%), myocardium (14%), necrotic core (12%), and organising thrombus (7%). • The tissue/debris pattern was similar in both filters. • Patients treated with a SAPIEN 3 valve had larger particles (≥1,000 µm) compared to those treated with an Evolut R or a Lotus valve. • The total tissue area was significantly greater in patients treated with a SAPIEN 3 (21.3±15.1 mm²) and Evolut R (20.1±19.0 mm²) valve compared to those treated with a Lotus valve (7.1±6.3 mm²) (p=0.0014). • Two strokes within 48 hours after TAVR were reported, 1 non-disabling stroke on day 1 in a patient treated with the Lotus valve and 1 disabling stroke on day 2 in a patient treated with the Evolut R.
Latib et al ⁴¹ JACC Cardiovasc Interv. (2020)	Emblak	20	Evolut R: 11 (55%), ACURATE neo-4 (20%), Portico: 2 (10%), Evolut PRO: 1 (5%), SAPIEN 3: 1 (5%)	90%	<ul style="list-style-type: none"> • Red blood cells in 18 filters (100%), fibrin strands in 15 (75.0%), collagen strands in 9 (45.0%) with a mean strand length of 1.216±1.53 mm; calcium debris in 5 (25.0%), and arterial wall in 1 (5%). • No neurological events were reported. • DW-MRI indicated 95% (19) of patients with new brain ischaemic defects at 2 to 5 days post-TAVR.
Kroon et al ¹⁰³ EuroIntervention (2021)	SENTINEL	328	Evolut R/PRO: 123 (37.5%), SAPIEN 3: 113 (34.5%), Lotus: 92 (28%)	98%	<ul style="list-style-type: none"> • The captured debris consisted of thrombus (90%), aortic valve tissue (70%), foreign material (49%), endothelium (30%), collagen (25%), calcification (22%), and myocardium (10%). • The treatment of native (functional) bicuspid valves (OR 2.91; p=0.02) and the use of the Lotus valve (OR 2.44; p=0.02) were significantly associated with the highest risk for dislodging particles ≥1,000 µm. • Valve repositioning was independently associated with larger amounts of captured debris (OR 2.96; p=0.004). • Four patients suffered a post-TAVR stroke, all with the Lotus valve, and particles >1,000 µm were present in the filters of all patients.

Table 3. Summary of studies using CEPDs reporting histopathological analysis (cont'd).

Study	Device	N	Valve type	Percentage of patients with particles captured	Histopathological analysis/other clinical findings
AORTIC PROCEDURES					
Donà et al ¹⁰⁴ J Pers. Med. (2022)	SENTINEL	213	Self-expanding valves (63.9%): Portico (13.6%), ACURATE neo (34.0%), Evolut R (14.6%), Centara valve (1.0%), Allegra valve (0.7%), Balloon-expandable valves or mechanically expanded valves (36.1%, data not specified).	91%	<ul style="list-style-type: none"> • Debris was captured in 91% of filters, and in 64% histopathological analysis was conducted (only in captured particles >2 mm in size). • The captured tissue consisted of valve tissue (62.5%), arterial wall (37.5%), atherosclerotic plaque (32.5%), myocardium (10.0%), acute thrombus (7.5%), organised thrombus (7.5%), and foreign material (2.5%). • 24 (11.3%) patients received only the brachiocephalic trunk filter. • At 90-day follow-up, 20 (4.9%) cerebrovascular events occurred, of which 10 (2.4%) were disabling strokes. • In the CEPD group, 5 cerebrovascular events were recorded: 2 (2/183, 1.1%) occurred in patients with correctly positioned CPS, both affecting the territory of the left vertebral artery (not covered by the SENTINEL), and 3 events occurred (3/24: 12.5%) in patients with incorrectly positioned CPS; two of them in the territory of the left carotid or vertebral arteries (which were not covered by the distal filter), and one in the right mid-cerebral artery territory, indicating incomplete coverage of the right brachiocephalic trunk/the right carotid artery. • The incidence of cerebrovascular events was reduced in the CEPD group by 70% (CEPD 2.3% vs no CEPD 7.6%, p=0.02).
Kawakami et al ¹⁰⁵ Circ Cardiovasc Interv. (2022)	SENTINEL	49	Evolut PRO: 27 (55%), SAPIEN 3: 22 (45%)	100%	<ul style="list-style-type: none"> • Arterial wall (98% of cases), acute thrombus (96%), valve tissue (71%), calcification (55%), and foreign material (43%), myocardial tissue (20%), organising thrombus (4%), and necrotic core (4%). • Most captured debris had a size of <500 µm (78% were 150-500 µm). Nearly 5% of the captured particles were ≥1,000 µm, and these were detected in 67% of cases. • Transcatheter heart valve type did not impact the debris tissue types, particle numbers, or sizes. • Calcified particles were more common in patients treated with predilatation (71% vs 43%, p=0.046). However, predilatation or post-dilatation did not alter particle numbers or sizes. • Low risk: 86%, and intermediate risk: 14%. • The rates of death or stroke within 30 days post-TAVR were 2% (1/49, due to myocardial infarction) and 4% (2/49), respectively.
MITRAL PROCEDURES					
Freker et al ⁵¹ JACC Cardiovasc Interv. (2016)	SENTINEL	14	MitraClip for severe functional mitral regurgitation	100%	<ul style="list-style-type: none"> • The most common tissue types were acute thrombus and small foreign material (hydrogel) in 12 patients (87.5% each), fibroelastic tissue (valve tissue and/or superficial atrial wall tissue) in 9 (64.3%), organising thrombus in 4 (28.6%), any thrombus in 2 (14.3%), and myocardium in 2 (14.3%). • Combination of thrombus, valve/atrial wall tissue and foreign material in 8 (57%), and any thrombus plus foreign material only in 3 (21%). • Calcification was not seen in any filter. • The median cumulative particle area per patient of 2.46 mm² (QR 0.44 to 3.67), median maximum particle diameter of 295 µm (QR 104 to 509). • Larger particles were identified more frequently in proximal versus distal filters • Patients treated with 2 clips had a larger maximum particle diameter compared with 1 clip (median 402 vs 134 µm; p<0.0001) • Cumulative areas of debris captured in proximal and distal filters were 1.35 mm² (QR 0.30 to 2.09) and 1.07 mm² (QR 63 to 442) per patient of 2.46 µm (QR 0.44-3.67), respectively, with maximum diameters of 346 µm (QR 211-555) and 217 µm (QR 63-442), respectively (p<0.0001). • No cerebrovascular events were reported.
COMBINED AORTIC AND MITRAL PROCEDURES					
Schmit et al ⁶⁵ Heart (2016)	SENTINEL	15	Evolut R: 8 (62%), CoreValve: 3 (23%), SAPIEN 3: 1 (8%), SAPIEN XT: 1 (8%)	100% in proximal filters and 87% in distal filters	<ul style="list-style-type: none"> • 13 degenerated aortic and 2 degenerated mitral surgical or transcatheter bioprostheses were treated with transcatheter valve-in-valve (ViV) using cerebral protection • All patients underwent a ViV TAVR procedure. • For ViV in the aortic position (CoreValve, n=3; Evolut R, n=8; SAPIEN XT, n=1; SAPIEN 3, n=1). • For ViV in the mitral position (SAPIEN XT, n=2). • Acute thrombus was the most common type of debris, captured in all 15 proximal filters and 12 (80%) distal filters; arterial wall tissue in 80% (12/15), calcification in 73% (11/15), valve tissue in 60% (9/15), foreign material in 27% (4/15), organised thrombus in 33% (5/15), and myocardium in 13% (2/15). • Platelet aggregation to the biological debris was seen in all patients in whom acute thrombus and biological debris (arterial wall, calcification, and valve tissue) were found. Also, all samples containing acute thrombus and foreign material showed platelet aggregation. • Combination of all types of debris was the most common combination (n=5, 33%) followed by thrombus in combination with arterial wall and calcification (n=4, 27%). • Overall, 2,862 particles were found in all filters, with 455 particles >150 mm. • The median of particles per patient in the filter pairs was 123, with a median of 20 particles per patient being >150 mm. • The average median particle diameter per patient was 47 mm (minimum of 32 mm, maximum of 88 mm). • A trend towards higher total particle counts in proximal compared with distal filters (median 78 vs 39, respectively; p=0.065) was reported. • No differences between proximal and distal filters were observed for average particle diameters or the number of particles ≥150 mm. • No neurological event was seen during hospitalisation. • One (7%) stroke occurred 5 months after the procedure.
CEPD: cerebral embolic protection device; CPS: cerebral protection system; DW-MRI: diffusion-weighted magnetic resonance imaging; QR: interquartile range; NR: not reported; OR: odds ratio; TA: transaortic; TAVR: transcatheter aortic valve replacement; TF: transfemoral; TIA: transient ischaemic attack; TS: transsubclavian; ViV: valve-in-valve					

Table 4. Main features of an ideal CEPD.

Provide complete protection to the cerebral circulation
Easy to use, deploy, and retrieve
Harmless and safe
Effective to prevent small and large emboli
Feasible for all anatomies (one size fits all)
No/minimal interaction with the TAVR delivery systems
Optimal visibility under fluoroscopy
Maintained stability throughout the procedure
Absence of cerebral flow obstruction
Low thrombogenicity
Low risk of causing dissections, carotid or aortic plaque displacement or rupture during device deployment, positioning, and retrieval, and during passage of the TAVR delivery system in the aortic valve and ascending aorta
As low profile as possible to avoid access site complications
Low cost
Captures and removes all cerebral and non-cerebral debris
Versatile to be used for other left heart procedures
CEPD: cerebral embolic protection device; TAVR: transcatheter aortic valve replacement

these studies in demonstrating a consistent stroke reduction benefit of the SENTINEL CEPD during TAVR. Other retrospective analyses from Alkhouli et al³⁴, Seeger et al³⁵, and an analysis from Ulm³⁶ were similarly discordant in their findings of benefit (or not) with the use of a CEPD during TAVR.

The recently published PROTECTED TAVR (Stroke PROTECTION With SENTinel During Transcatheter Aortic Valve Replacement) trial³⁷ was the first randomised, open-label, multicentre, all-comer trial powered for clinical endpoints. It enrolled 3,000 patients undergoing transfemoral TAVR with all commercially available transcatheter heart valves, to receive TAVR plus the SENTINEL device (CEPD group: 1,501 patients) or TAVR with no CEPD (control group: 1,499 patients). The primary endpoint was all stroke (haemorrhagic, ischaemic, or undetermined status; disabling or non-disabling) up to 72 hours post-TAVR procedure or hospital discharge using NeuroARC definitions³⁰. Successful device deployment was achieved in 94.4% of patients, and 1 patient (0.1%) developed a vascular complication at the CEPD access site. SENTINEL use did not significantly reduce the incidence of stroke within 72 hours post-TAVR or before hospital discharge compared to the control group (2.3% vs 2.9%; $p=0.30$). Disabling stroke (a secondary endpoint) was less frequent in the CEPD group (0.5%) compared to the control group (1.3%; difference -0.8 percentage points; 95% CI: -1.5 to -0.1). Also, the incidence of all-cause death (0.5% vs 0.3%), stroke, transient ischaemic attack (TIA), or delirium (3.1% vs 3.7%), and acute kidney injury (AKI; 0.5% vs 0.5%) were similar between groups. The number needed to treat to prevent 1 disabling stroke was 125 patients. Although the device proved to be safe and a possible effect on disabling strokes (a secondary

endpoint) was seen, the lack of efficacy and clear clinical benefit might challenge its use in daily practice, and questions continue to arise regarding its cost-effectiveness, especially in single-payer health systems. **Figure 3** summarises the stroke reduction obtained by the SENTINEL CEPD in clinical trials.

THE TRIGUARD 3 CEREBRAL PROTECTION DEVICE

The TriGUARD 3 Cerebral Protection Device is a deflection device positioned to protect all 3 branches of the aortic arch, including the left subclavian artery. It is placed via a transfemoral 9 Fr femoral arterial sheath which allows for concomitant use of a 6 Fr pigtail catheter. The device is composed of a semipermeable nitinol mesh with pores of 115x145 μm which deflect particles larger than 140 μm . The mesh is heparin-coated to reduce the risk of thrombus formation. The circumferential pressure of the device in the aortic arch and the nitinol device shaft holds the device in position during TAVR^{24,25}.

The feasibility and safety of this device was investigated in the DEFLECT I³⁸ and DEFLECT II³⁹ trials, which were prospective, single-arm studies ($n=37$ and 14 patients, respectively). DEFLECT I³⁸ showed a similar presence of new cerebral ischaemic lesions on DW-MRI to historical controls (82 vs 76%; $p=\text{not significant}$). Similarly, in the DEFLECT II trial³⁹, comparing the DW-MRIs of these patients to a historical control group showed no reduction in the number of lesions (median 5.5 vs 5.0; $p=0.86$). DEFLECT III⁴⁰ ($n=85$ patients) was a single-blind multicentre randomised trial in which TAVR patients were randomised to either a CEPD ($n=46$) with the TriGUARD system or to no CEPD ($n=39$). Device success was achieved in 88.9% (40/45) of patients. The primary in-hospital procedural safety endpoints (death, stroke, life-threatening or disabling bleeding, stage 2 or 3 AKI, or major vascular complications) were not statistically different (21.7% of the TriGUARD HDH group compared to 30.8% of the control group; $p=0.34$).

The REFLECT I trial ($n=258$ patients of the initially planned 375 patients) was a multicentre (20 US and 6 European centres), randomised controlled trial that evaluated the safety, efficacy, and performance of the TriGUARD system in patients undergoing TAVR²⁴. Prior to completing enrolment, the study was suspended at the recommendation of the data safety monitoring committee. The primary efficacy endpoint was a hierarchical composite of (i) all-cause mortality or any stroke at 30 days, (ii) National Institutes of Health Stroke Scale worsening at 2-5 days or Montreal Cognitive Assessment worsening at 30 days, and (iii) total volume of cerebral ischaemic lesions detected by DW-MRI at 2-5 days. Complete coverage of all 3 cerebral vessels throughout the TAVR procedure was achieved in 57.3% (78/136) of cases. The primary safety outcome was met compared with the performance goal (21.8% vs 34.4%; $p<0.0001$). The primary hierarchical efficacy endpoint was not significantly different between groups.

The REFLECT II US trial²⁵ enrolled 220 of the planned 345 patients (63.8%) across 18 US sites. After the FDA suggested that enrolment be suspended for unblinded safety data assessment,

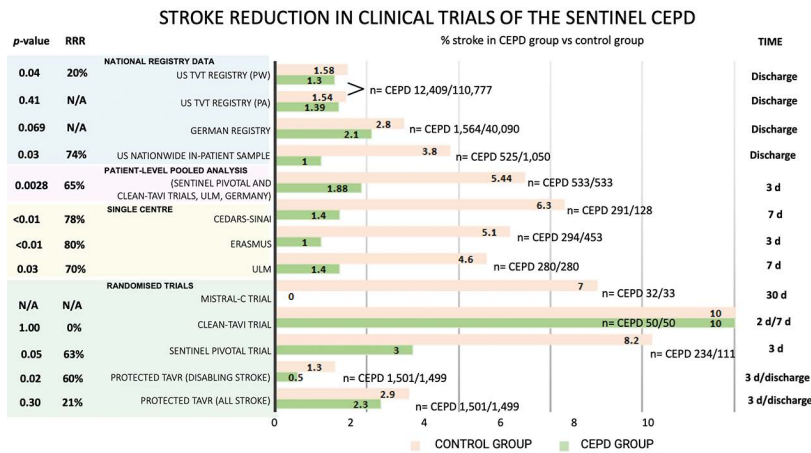


Figure 3. Stroke reduction obtained by SENTINEL CEPD in clinical trials. CEPD: cerebral embolic protection devices; d: days; N/A: not applicable; PA: primary analysis; PW: propensity-weighted; RRR: relative risk reduction

the sponsor discontinued the study early. Complete cerebral coverage was achieved in 59.7% (94/157) of cases, device interaction was reported in 9.6% (15/157). The trial met its primary safety endpoint compared with the performance goal (15.9 vs 34.4%; $p < 0.0001$). The primary hierarchical efficacy endpoint at 30 days (death or stroke at 30 days, National Institutes of Health Stroke Scale worsening in hospital, and cerebral ischaemic lesions on DW-MRI at 2 to 5 days) was not met.

CEPDs currently under development

EMBLOK EMBOLIC PROTECTION SYSTEM

The Emblok Embolic Protection System is a device designed to protect all supra-aortic vessels by a full circumferential coverage of the aortic arch. The delivery system is 11 Fr, compatible to be deployed through a single access site supported by a 0.035" guide-wire and incorporates an integrated 4 Fr radiopaque pigtail catheter which provides constant visualisation, from which an aortogram can be performed both for the CEPD and valve deployment⁴¹. The filter is made of a polyurethane mesh with a pore size of 125 μm , supported by a nitinol frame positioned just proximal to the brachiocephalic trunk. Once the transcatheter aortic valve is advanced to the level of the ascending aorta and before the transcatheter valve is positioned across the native aortic valve, the conical filter is unsheathed, then, the filter frame is pulled back towards the aortic wall to maximise apposition and sealing. Once the transcatheter valve is deployed, the Emblok system must be recaptured in order to retrieve the transcatheter delivery system from the body⁴¹. Early human experience is summarised in **Table 1**.

PROTEMBO CEREBRAL PROTECTION SYSTEM

The ProtEmbo Cerebral Protection System is a temporary, intra-aortic embolic deflection filter used during transcatheter heart interventions and is the only current device that can be positioned through a 6 Fr left radial access⁴². ProtEmbo is designed to provide complete cerebral protection; it is inserted at the beginning of the procedure prior to TAVR and removed

following TAVR completion. The device consists of (i) a heparin-coated mesh with 60 μm pores (currently the smallest pore size of CEPDs under development), (ii) a self-expanding nitinol frame that provides complete coverage of all supra-aortic vessels with radiopaque markers for fluoroscopic visualisation and precise device placement and (iii) a delivery unit. The device is fully retrievable and recapturable; it is delivered unexpanded and deployed by unsheathing the self-expanding filter to cover the orifice of all 3 cerebral vessels (brachiocephalic trunk, left common carotid, and left subclavian arteries). A handle provides a simple user interface for preparation, delivery, deployment and removal of the device. The device is loaded into a commercially available delivery catheter and placed into the aortic arch using a commercially available guiding sheath via the left radial or brachial artery⁴². The first-generation ProtEmbo device was shown to be safe and feasible in the first-in-human PROTEMBO SF Trial ($n=4$ patients; ClinicalTrials.gov: NCT03325283) at 2 clinical sites in Europe⁴³. The PROTEMBO C Trial ($n=41$ patients at 8 European centres) interim results have been published⁴² and are summarised in **Table 1**. The company will conduct the ProtEmbo IDE trial in up to 500 patients in the USA and Europe starting in the third-quarter (Q3) of 2023.

EMBOLINER TOTAL EMBOLIC PROTECTION DEVICE

The Emboliner total embolic protection device is a cylindrical nitinol mesh filter with a pore size of 125 μm that circumferentially conforms to the aortic arch to cover all 3 cerebral branch vessels. The device captures and removes debris generated during TAVR. The delivery system is 10 Fr and integrates a 6 Fr pigtail and an expandable access port to allow passage of the transcatheter valve⁴⁴. SafePass clinical program results^{45,46} are summarised in **Table 1**. Although the study results are yet to be published, the company launched a US-based pivotal trial this year for FDA and CE approval comparing Emboliner versus SENTINEL in 500 TAVR patients (plus 40 Emboliner roll-in cases) with a 1:1

randomisation (ClinicalTrials.gov: NCT05684146). The primary endpoint is the 30-day combined major adverse cardiac and cerebrovascular event (MACCE) rate (all death, stroke and stage 3 AKI). Results are expected in December 2024.

CAPTIS EMBOLIC PROTECTION SYSTEM

The CAPTIS embolic protection system has a combined mechanism of action: deflection of embolic particles at the level of the aortic arch and capture and removal of debris at the level of the descending aorta. It is composed of a filter made of PEEK (poly-ether-ether-ketone), with a pore size of 115x145 µm, attached to a nitinol frame with a deflector configuration in the aortic arch covering the 3 cerebral branch vessels and collector pockets adapted circumferentially to the descending aorta anatomy, joined by a nitinol rail and an anchoring segment as a stabilisation mechanism. The 16 Fr delivery system uses the same femoral access as TAVR without the need for an extra vascular access⁴⁷. The first-in-human (FIH) results, presented at EuroPCR in 2022, are summarised in **Table 1**.

FLOWER EMBOLIC PROTECTION DEVICE

The FLOWer device, formerly the Embrace filter, is an embolic protection system designed to protect cerebral and peripheral vessels. The device is a cylindrical mesh filter with a pore size of 70 µm attached to a frame that adapts circumferentially to the aortic arch to cover all the cerebral branch vessels. The device comes in 3 different sizes and aims to capture and remove debris produced during TAVR. The delivery system is 12 Fr and integrates a 5 Fr pigtail and a port compatible with all TAVR delivery systems. An *in vitro* test reported by the company (not published) showed 99% of particles >150 µm captured at the level of the aortic arch (cerebral protection) and 84% distal to the aortic arch towards downstream circulation (systemic protection), with a calculated *in vitro* pressure drop of 6.6 mmHg at 4.5 L/min cardiac output through the Embrace filter⁴⁸. Preliminary data from the NAUTILUS FIH study (ClinicalTrials.gov: NCT04704258), presented at EuroPCR in 2023⁴⁹, are summarised in **Table 1**.

POINT-GUARD DYNAMIC CEREBRAL EMBOLIC PROTECTION

The POINT-GUARD Dynamic Cerebral Embolic Protection is a second-generation device aimed to provide full aortic arch protection with maximum coverage of all great arch vessels and inlets to the brain. The device consists of an ultrathin flexible filter mesh attached to a dynamic frame assembly with dual-edge perimeter seal, proximal and distal anchoring segments to provide stability, an anchor on the proximal drive shaft to prevent position shift, and a proximal pouch for embolic capture. The device has an adaptive asymmetric configuration that allows it to adapt to the angulation of the aortic arch and provide complete anterior and posterior coverage. The first-generation device was tested in the POINT-GUARD First-In-Human CENTER Study (n=4 patients) during elective transfemoral TAVR (no published data yet available)⁵⁰ (**Table 1**).

Non-TAVR use of CEPDs

The risk of debris embolisation (atheroma or thrombus) during non-TAVR structural heart procedures (i.e., transcatheter mitral valve therapies, left atrial appendage occlusion [LAAO]), is not negligible⁵¹⁻⁵³ (**Table 5**). Similar to TAVR, cerebral embolisation may be asymptomatic and detected solely on brain imaging or may present as major clinical events impacting morbidity and mortality. However, existing studies evaluating cerebral embolisation in non-TAVR procedures have lacked formal neurological adjudication. Consequently, the real incidence of neurological events may be underreported (**Central illustration**).

TRANSCATHETER EDGE-TO-EDGE REPAIR AND MITRAL VALVE REPLACEMENT

In mitral valve interventions, stroke rates are considerably lower than those reported in TAVR, yet still significant. In the COAPT trial⁵⁴, the stroke rate was 0.7% at 30 days, while in the MITRA-FR trial⁵⁵, authors reported a periprocedural incidence of 1.4%. A recent systematic review and meta-analysis⁵⁶ showed an incidence of 2.9% of periprocedural strokes in 941 patients who underwent transcatheter edge-to-edge repair (TEER). In a small study (14 patients) using the SENTINEL system during TEER⁵¹, microscopic debris were detected in all 28 filters, consisting mainly of acute thrombus (85.7%) or fragments of foreign material such as hydrophilic device coating (85.7%) (**Table 3**). As in TAVR, the spectrum of brain damage ranges from overt stroke to silent ischaemic brain injury. In a small study, new brain lesions were detected using DW-MRI in 23 (85.7%) of 27 patients after TEER⁵⁷. These data are consistent with what was recently reported by Braemswig et al⁵⁸, who observed an incidence up to 87% (21 out of 24 patients) of cerebral ischaemic injuries in TEER procedures, assessed by pre-and postprocedural DW-MRI, and a 16.6% incidence of overt stroke (9 out of 54 patients). Using periprocedural transcranial Doppler (TCD) monitoring, the authors identified that the procedural step with the highest numbers of microembolic signals towards the brain was device interaction with the mitral valve.

Although few published data evaluate the incidence of stroke during percutaneous mitral annuloplasty and transcatheter mitral valve replacement (TMVR), an acute stroke incidence of around 3% has been reported (**Table 3**). There are no reports so far of CEPD use during TMVR.

LEFT ATRIAL APPENDAGE OCCLUSION

The incidence of stroke during left atrial appendage occlusion (LAAO) procedures is between 0.2% and 1.2% across a range of LAAO devices (**Table 3**). Limited data exist on outcomes after LAAO in the presence of persistent thrombus within the left atrial appendage (LAA) in patients considered to be poor candidates for long-term oral anticoagulant (OAC) use or in patients where OACs have failed to dissolve LAA thrombus. In a systematic review of patient-level data of cases using a CEPD in 17 of 58 (29%) patients, no periprocedural stroke was reported⁵⁹. Microembolic signals have been found in 100%

Table 5. Periprocedural cerebral embolic events during non-TAVR procedures.

	Transcatheter edge-to-edge repair (TEER) 55-58,106	Transcatheter mitral valve replacement (TMVR) ¹⁰⁷⁻¹¹¹	Percutaneous mitral annuloplasty (PMA) ¹¹²⁻¹¹⁴	Left atrial appendage occlusion (LAO) ^{60-62,115-121}	Atrial septal defect (ASD) & patent foramen ovale (PFO) 122-124	Catheter ablation 63,65-67,125-132	Thoracic endovascular aortic repair (TEVAR) 70-73,75,76,79,81,134,135
Study design	Retrospective, RCT, systematic review and meta-analysis	Prospective, single-arm	Prospective, single-arm	Prospective observational, RCT, systematic review	Prospective, single-arm	Retrospective, prospective observational	Retrospective, prospective observational
Stroke/TIA	3.3%	7.1%	3.0%	0.2%	2.5%	1.0%	5.1%
Number of patients	1,176	14	101	39,775	81	62,154	980
Number of events	39	1	3	81	2	608	50
Cerebral embolic lesions on DW-MRI	86.3%	NR	NR	30.6%	6.1%	27.1%	74.6%
Number of patients	51	NR	NR	72	65	317	59
Number of patients with new lesions	44	NR	NR	22	4	86	44
HITS on transcranial Doppler	100%	NR	NR	NR	100%	NR	100%
Number of patients	54	NR	NR	NR	16	NR	80
Number of HITS	152 [IQR 94-280]	NR	NR	NR	31.5 [IQR 3-113]	NR	268 (IQR 71-521)

DW-MRI: diffusion-weighted magnetic resonance imaging; HITS: high-intensity transient signals; IQR: interquartile range; NR: not reported; TIA: transient ischaemic attack; TAVR: transcatheter aortic valve replacement

of patients during LAO with the WATCHMAN device (Boston Scientific), alongside new silent cerebral embolic events in over one-third of patients within 24 hours after LAO, assessed by TCD monitoring and DW-MRI, respectively⁶⁰. Data from different studies using a variety of LAO devices reported an incidence of new brain lesions between 4.8% and 52.0% within 2 days after LAO^{61,62}.

CATHETER ABLATION

The reported rates for periprocedural stroke or transient ischaemic attack range from 0.38% to 7.00% during ablation procedures^{63,64}. The first 24 hours post-ablation represent a high-risk period, which continues for an additional 2 weeks⁶⁴. Also, new brain ischaemic lesions have been detected on postprocedural DW-MRI in up to 58% of patients undergoing routine left ventricular ablation procedures⁶⁵ and as high as 38% after left atrial catheter ablation^{66,67}.

The evidence for CEPD use during cardiac ablation is limited to a small series of cases in patients undergoing ventricular tachycardia ablation with confirmed high risk of periprocedural stroke (left atrial appendage thrombus, left ventricular apical thrombus, complex aortic plaque)^{68,69}. No cerebrovascular events were reported, but debris was captured in most cases.

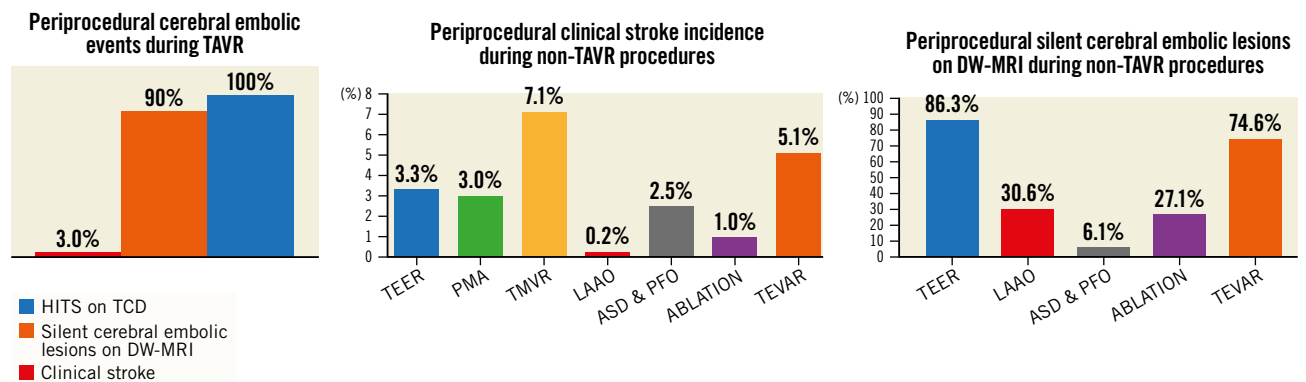
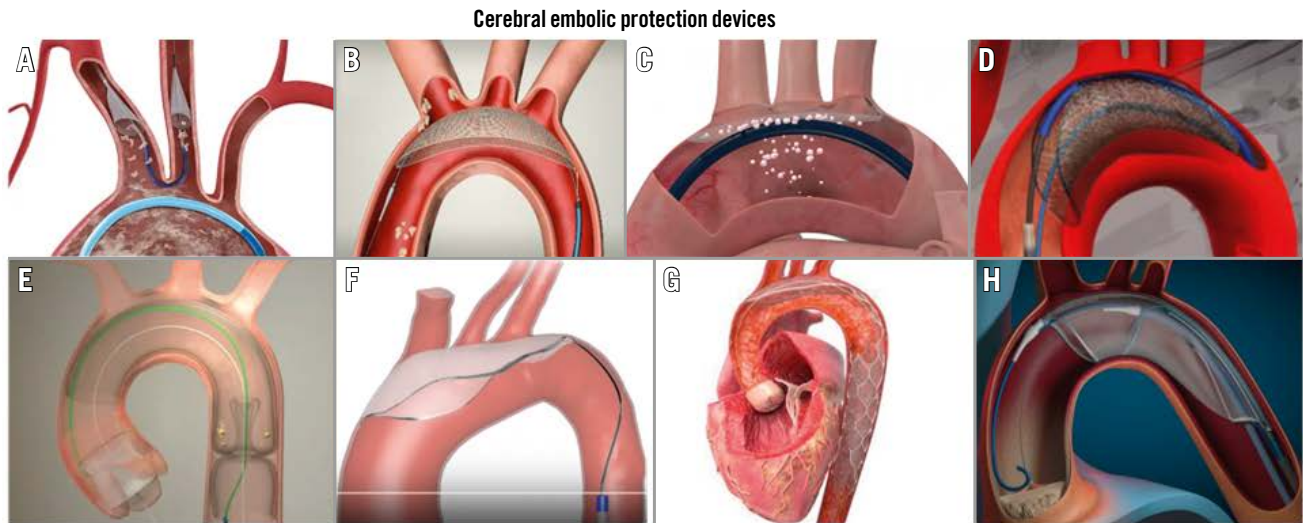
THORACIC ENDOVASCULAR AORTIC REPAIR PROCEDURES

Stroke occurs in 3 to 8% of patients undergoing thoracic endovascular aortic repair (TEVAR)^{70,71}; microembolic signals

assessed by TCD are detected in 100% of patients during the procedure⁷², and in over 80% of cases, postprocedural DW-MRI demonstrated the presence of silent stroke^{73,74}. This has been associated with significant neurocognitive decline and linked with considerably increased morbidity and mortality⁷⁵. It is estimated these numbers are higher in ascending aortic TEVAR. Consequently, efforts have been made to reduce the risk of periprocedural stroke during TEVAR^{76,77}. There are several case reports and series of patients who have undergone TEVAR with a CEPD⁷⁸⁻⁸⁰. The authors noted that the use of CEPD appeared to reduce the size and distribution of new cerebral infarcts compared with previously reported neuroimaging studies of unprotected TEVAR procedures, suggesting improved protection for the anterior (protected) circulation^{73,81}. Interestingly, a greater number of high-intensity signals were detected during CEPD manipulation and deployment (median 124 [interquartile range IQR 59-146]) compared to during stent manipulation and TEVAR deployment (median 82 [IQR 73-142])⁷⁹.

PERMANENT CEREBRAL EMBOLIC PROTECTION

The Vine filter (Javelin Medical) is a permanent, bilateral, common carotid artery filter made of a single nitinol wire with a circular cross-section (diameter 240 µm) developed to prevent emboli >1.4 mm in size from reaching the cerebral anterior circulation (**Figure 4**). The implantation is ultrasound-guided using a 22 gauge insertion needle via a completely percutaneous

CENTRAL ILLUSTRATION Cerebral embolic protection devices and data on TAVR and non-TAVR procedures.

A) SENTINEL; B) TriGUARD 3; C) ProtEmbo; D) Emblok; E) Emboliner; F) POINT-GUARD; G) CAPTIS; H) FLOWer
 ASD: atrial septal defect; DW-MRI: diffusion-weighted magnetic resonance imaging; HITS: high-intensity transient signal; LAAO: left atrial appendage occlusion; PFO: patent foramen ovale; PMA: percutaneous mitral annuloplasty; TAVR: transcatheter aortic valve replacement; TCD: transcranial Doppler; TEER: transcatheter edge-to-edge repair; TEVAR: thoracic endovascular aortic repair; TMVR: transcatheter mitral valve replacement

approach. Preliminary data have been promising⁸². A large clinical trial to further evaluate the efficacy and safety of this approach is planned (ClinicalTrials.gov: NCT05723926).

Current controversies

COMPLETE VERSUS INCOMPLETE CEREBRAL EMBOLIC PROTECTION

Current data notionally support the use of CEPDs that offer complete brain protection during transcatheter heart interventions, when feasible, since the left vertebral artery accounts for up to 20% of total brain perfusion⁸³⁻⁸⁵. The amount and size of debris that passes through the left vertebral artery during TAVR is comparable to the amounts that pass through the brachiocephalic trunk and left common carotid artery^{15,16,83,86}. The clinical and surrogate

endpoint (MRI, cognitive impairment) outcomes are anticipated to be superior with complete versus partial CEPDs. However, this concept will require confirmation in prospective randomised studies.

DEFLECTION VERSUS COLLECTION OF DEBRIS DURING TRANSCATHETER CARDIAC INTERVENTIONS

Likewise, it stands to reason that entrapping and extracting debris produced during transcatheter heart interventions may offer some advantage over deflection of particles away from the brain towards the distal circulation. However, this concept has yet to be demonstrated in any study to date, and it is not supported by the literature in terms of a lower incidence of clinical events, such as acute renal failure or distal limb complications arising from embolic debris. In

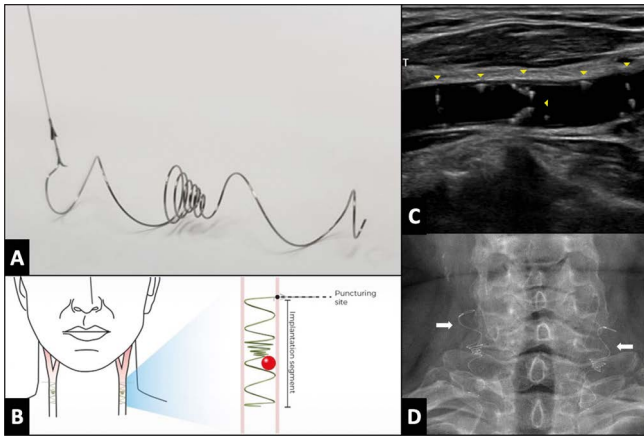


Figure 4. The Vine (Javelin Medical) filter. *A) A permanent, bilateral, common carotid artery (CCA) filter. B) Illustration of the filter position in both carotid arteries. C) Transcarotid echography in longitudinal view showing the filter implanted in the right common carotid artery (yellow arrowheads). D) Fluoroscopic view showing both carotid filters in the anteroposterior view (white arrows).*

addition, the risk/benefit ratio (in terms of excess vascular complication rates arising from a large-bore contralateral femoral access site versus stroke/peripheral embolic protection/mitigation) must be preserved in the setting of using larger-calibre devices via the femoral artery to extract as much debris as possible during transcatheter interventions for total body protection. A current niche area that is anticipated to grow exponentially in the future involves techniques to resect native or transcatheter heart valve leaflets⁸⁷. These procedures carry a high risk of large-sized debris embolisation wherein devices designed for full body embolic protection and total debris entrapment would notionally stand to play an important role. Furthermore, given the similar incidence of periprocedural stroke during transcatheter mitral edge-to-edge repair therapies (large-bore venous procedures) as compared with TAVR, avoiding large-bore femoral arterial access would be ideal if CEPDs were to ultimately find a place for stroke/brain protection during these procedures.

CEPD USE DURING NON-FEMORAL TAVR PROCEDURES

The increasing application of TAVR in populations with complex iliofemoral vascular access (severe calcification and/or tortuosity), particularly in patients harbouring an anatomy incompatible with the sizes of current delivery systems, has resulted in alternate access TAVR procedures being performed in a non-negligible proportion of patients⁸⁸. To date, there are no data on the preferential choice of any specific type of CEPD based on the vascular access route. This choice should consider the technical characteristics of TAVR, taking special care when using CEPDs via the radial route in patients with transcarotid, axillary or subclavian TAVR and with CEPDs via the femoral route in patients with transcaval or transaortic TAVR. The effectiveness and safety of CEPDs can be altered by their interaction with the various catheters used in TAVR and with modifications to perform TAVR through alternative vascular access.

CEPD DURING SAVR

The reported stroke rates after SAVR range widely (from 1 to 17%)⁸⁹⁻⁹¹. In a propensity-matched study including 1,204 pairs of patients undergoing TAVR or SAVR from the PARTNER trials, Kapadia et al⁹² found a greater 30-day major stroke incidence after SAVR compared to TAVR (3.9% vs 2.2%, respectively; $p=0.018$) and an associated decline in quality of life at 1 year in all patients who suffered a major stroke from both groups. Also, the incidence of subclinical brain lesions is considerable (up to 60%)⁹⁰. A randomised trial compared 2 types of CEPD ($n=118$ for suction-based extraction and $n=133$ for intra-aortic filtration device) versus a standard aortic cannula (control; $n=132$) at the time of SAVR⁹³. The study failed to demonstrate prevention of either clinical stroke or imaging-based cerebral infarction, despite capturing embolic debris in the majority of the embolic protection devices. Although attractive, the use of transcatheter CEPDs has not been reported in this setting.

Upcoming trials

A large, randomised trial (ongoing) is likely to provide definitive evidence on the efficacy of the SENTINEL CEPD in the clinical prevention of stroke during TAVR, as well as several other studies which will provide data for various CEPDs on the prevention of procedural stroke and ischaemic brain injury by DW-MRI (Figure 5).

The BHF PROTECT-TAVI (British Heart Foundation Randomised Trial of Routine Cerebral Embolic Protection in Transcatheter Aortic Valve Implantation) ($n=7,730$), is an open-label, outcome-adjudicated, multicentre, all-comer randomised clinical trial in the UK that will randomise patients undergoing TAVR by any access route to CEPD (with the SENTINEL CEPD) or no CEPD, with no specific exclusion criteria. The primary outcome measure is stroke at 72 hours post-TAVR. Amongst a range of secondary outcome measures, a cost-effectiveness analysis at 12 months will be performed. As of 30 June 2023, 59% of the total population (4,534 patients) have been enrolled in the trial⁹⁴. An interim analysis is planned after the inclusion of 3,865 participants (50% of sample size). Final results are expected in July 2026. One of the main differences with the PROTECTED TAVR trial is there is no mandatory neurological evaluation by a neurologist or by a stroke specialist, this may decrease non-disabling stroke detection. Also, enrolment bias could be diminished since the device is not approved for daily clinical use in the UK.

A pooled patient-level meta-analysis from both studies (PROSPERO registry) encompassing over 10,000 TAVR patients is planned and could provide a definitive answer on the SENTINEL device's efficacy in stroke prevention during TAVR⁹⁵. Although it will be very important information, the PROTECTED TAVR and BHF PROTECT-TAVI trials results are only relevant for SENTINEL CEPD. Hence, the results are not definitive for CEPD as a class of devices. Newer generations of CEPD will require their own specific clinical validation.

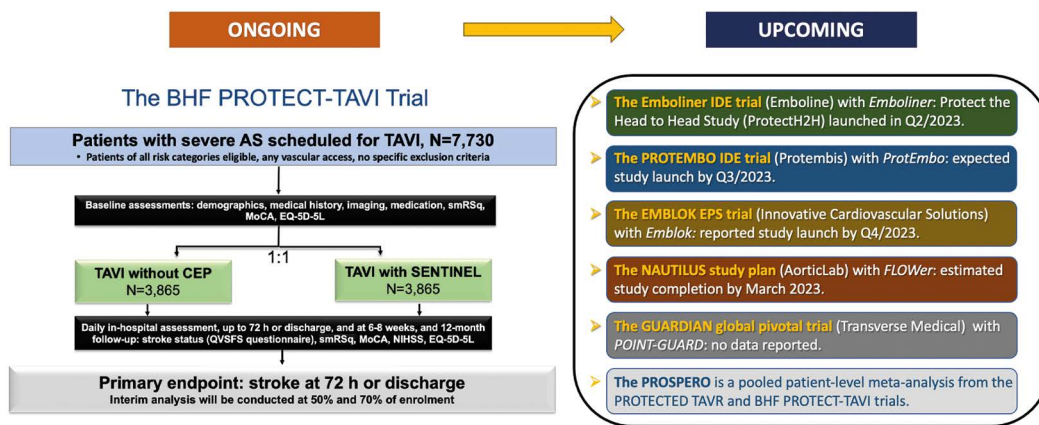


Figure 5. Main ongoing and upcoming clinical trials with CEPD. AS: aortic stenosis; BHF: British Heart Foundation; CEP(D): cerebral embolic protection (device); IDE: investigational device exemption; MoCA: Montreal Cognitive Assessment; NIHSS: National Institute of Health Stroke Score; Q: quarter; QVSFS: Questionnaire for Verifying Stroke-Free Status; smRSq: simplified modified Rankin Scale questionnaire; TAVI: transcatheter aortic valve implantation

Conclusions

Stroke following TAVR and various other transcatheter heart interventions remains largely unpredictable. In current TAVR practice, the rate of overt stroke during or soon after TAVR remains constant at between 2% and 4%^{4,5}, despite significant improvements in transcatheter heart valve design and TAVR techniques. Emerging evidence points to cerebral embolisation during other commonly performed left-sided transcatheter heart procedures, particularly mitral edge-to-edge repair interventions. Although cerebral embolisation appears ubiquitous during TAVR, its longer-term consequences upon cognition remain uncertain. While the first pivotal trial powered for clinical superiority of the SENTINEL CEPD failed to meet its primary endpoint, a much larger randomised trial is expected to provide further evidence of whether the current SENTINEL CEPD design significantly reduces the incidence of stroke during TAVR. Meanwhile, numerous other CEPDs remain under development offering a range of protective mechanisms and deployment strategies. There remains limited, yet emerging, data on the use of CEPDs in non-TAVR transcatheter heart and vascular procedures. Ultimately, the protective benefit of CEPDs in certain clinical scenarios or high-risk catheter-based vascular and structural interventions posing significant risk of stroke will require clinical evidence before CEPDs ultimately find their way onto the shelves of many cardiac catheterisation laboratories worldwide. Further studies are needed to determine CEPD's role and economic value in the rapidly expanding field of non-TAVR transcatheter interventions that are known to liberate considerable debris towards the brain.

Conflict of interest statement

V.A.J. Diaz is co-founder of Protembis GmbH and co-inventor of ProtEmbo. D. Mylotte is a consultant for Medtronic, Boston Scientific, and MicroPort. A. Lansky reports institutional research support from

Emblok, Emboline, and AorticLabs. R. Puri is a consultant to Protembis GmbH. The other authors have no conflicts of interest to declare.

References

- Otto CM, Nishimura RA, Bonow RO, Carabello BA, Erwin JP 3rd, Gentile F, Jneid H, Krieger EV, Mack M, McLeod C, O'Gara PT, Rigolin VH, Sundt TM 3rd, Thompson A, Toly C. 2020 ACC/AHA Guideline for the Management of Patients With Valvular Heart Disease: A Report of the American College of Cardiology/American Heart Association Joint Committee on Clinical Practice Guidelines. *Circulation*. 2021;143:e35-71.
- Vahanian A, Beyersdorf F, Praz F, Milojevic M, Baldus S, Bauersachs J, Capodanno D, Conradi L, De Bonis M, De Paulis R, Delgado V, Freemantle N, Gilard M, Haugaa KH, Jeppsson A, Juni P, Pierard L, Prendergast BD, Sádaba JR, Tribouilloy C, Wojakowski W. 2021 ESC/EACTS Guidelines for the management of valvular heart disease. *EuroIntervention*. 2022;17:e1126-96.
- Vlastra W, Jimenez-Quevedo P, Tchétché D, Chandrasekhar J, de Brito FS Jr, Barbanti M, Kornowski R, Latib A, D'Onofrio A, Ribichini F, Baan J, Tijssen JGP, De la Torre Hernandez JM, Dumonteil N, Sarmento-Leite R, Sartori S, Rosato S, Tarantini G, Lunardi M, Orvin K, Pagnesi M, Hernandez-Antolin R, Modine T, Dangas G, Mehran R, Piek JJ, Delewi R. Predictors, Incidence, and Outcomes of Patients Undergoing Transfemoral Transcatheter Aortic Valve Implantation Complicated by Stroke. *Circ Cardiovasc Interv*. 2019;12:e007546.
- Huded CP, Tuzcu EM, Krishnaswamy A, Mick SL, Kleiman NS, Svensson LG, Carroll J, Thourani VH, Kirtane AJ, Manandhar P, Kosinski AS, Vemulapalli S, Kapadia SR. Association Between Transcatheter Aortic Valve Replacement and Early Postprocedural Stroke. *JAMA*. 2019;321:2306-15.
- Muralidharan A, Thiagarajan K, Van Ham R, Gleason TG, Mulukutla S, Schindler JT, Jeevanantham V, Thirumala PD. Meta-Analysis of Perioperative Stroke and Mortality in Transcatheter Aortic Valve Implantation. *Am J Cardiol*. 2016;118:1031-45.
- Jennun P, Iversen HK, Ibsen R, Kjellberg J. Cost of stroke: a controlled national study evaluating societal effects on patients and their partners. *BMC Health Serv Res*. 2015;15:466.
- Tsao CW, Aday AW, Almarzooq ZI, Alonso A, Beaton AZ, Bittencourt MS, Boehme AK, Buxton AE, Carson AP, Commodore-Mensah Y, Elkind MSV, Evenson KR, Eze-Nliam C, Ferguson JF, Generoso G, Ho JE, Kalani R, Khan SS, Kissela BM, Knutson KL, Levine DA, Lewis TT, Liu J, Loop MS, Ma J, Mussolino ME, Navaneethan SD, Perak AM, Poudel R, Rezk-Hanna M, Roth GA, Schroeder EB, Shah SH, Thacker EL, VanWagner LB, Virani SS, Voeks JH, Wang NY, Yaffe K, Martin SS. Heart Disease and Stroke Statistics-2022 Update: A Report From the American Heart Association. *Circulation*. 2022;145:e153-639.
- Coylewright M, Palmer R, O'Neill ES, Robb JF, Fried TR. Patient-defined goals for the treatment of severe aortic stenosis: a qualitative analysis. *Health Expect*. 2016;19:1036-43.
- Sugiura K, Kohno T, Hayashida K, Fujisawa D, Kitakata H, Nakano N, Saito T, Hase H, Yoshijima N, Tsuruta H, Itabashi Y, Kohsaka S, Fukuda K. Elderly aortic

- stenosis patients' perspectives on treatment goals in transcatheter aortic valvular replacement. *ESC Heart Fail.* 2022;9:2695-702.
10. Guedeney P, Mehran R, Collet JP, Claessen BE, Ten Berg J, Dangas GD. Antithrombotic Therapy After Transcatheter Aortic Valve Replacement. *Circ Cardiovasc Interv.* 2019;12:e007411.
 11. Nombela-Franco L, Webb JG, de Jaegere PP, Toggweiler S, Nuis RJ, Dager AE, Amat-Santos IJ, Cheung A, Ye J, Binder RK, van der Boon RM, Van Mieghem N, Benitez LM, Pérez S, Lopez J, San Roman JA, Doyle D, Delarochellière R, Urena M, Leipsic J, Dumont E, Rodés-Cabau J. Timing, predictive factors, and prognostic value of cerebrovascular events in a large cohort of patients undergoing transcatheter aortic valve implantation. *Circulation.* 2012;126:3041-53.
 12. Bjursten H, Norrving B, Ragnarsson S. Late stroke after transcatheter aortic valve replacement: a nationwide study. *Sci Rep.* 2021;11:9593.
 13. Mack MJ, Leon MB, Thourani VH, Makkar R, Kodali SK, Russo M, Kapadia SR, Malaisrie SC, Cohen DJ, Pibarot P, Leipsic J, Hahn RT, Blanke P, Williams MR, McCabe JM, Brown DL, Babaliaros V, Goldman S, Szeto WY, Genevex P, Pershad A, Pocock SJ, Alu MC, Webb JG, Smith CR; PARTNER 3 Investigators. Transcatheter Aortic-Valve Replacement with a Balloon-Expandable Valve in Low-Risk Patients. *N Engl J Med.* 2019;380:1695-705.
 14. Kahlert P, Al-Rashid F, Döttger P, Mori K, Plicht B, Wendt D, Bergmann L, Kottenberg E, Schlamann M, Mummel P, Holle D, Thielmann M, Jakob HG, Konorza T, Heusch G, Erbel R, Eggebrecht H. Cerebral embolization during transcatheter aortic valve implantation: a transcranial Doppler study. *Circulation.* 2012;126:1245-55.
 15. Ghanem A, Müller A, Nähle CP, Kocurek J, Werner N, Hammerstingl C, Schild HH, Schwab JO, Mellert F, Fimmers R, Nickenig G, Thomas D. Risk and fate of cerebral embolism after transfemoral aortic valve implantation: a prospective pilot study with diffusion-weighted magnetic resonance imaging. *J Am Coll Cardiol.* 2010;55:1427-32.
 16. Kahlert P, Knipp SC, Schlamann M, Thielmann M, Al-Rashid F, Weber M, Johansson U, Wendt D, Jakob HG, Forsting M, Sack S, Erbel R, Eggebrecht H. Silent and apparent cerebral ischemia after percutaneous transfemoral aortic valve implantation: a diffusion-weighted magnetic resonance imaging study. *Circulation.* 2010;121:870-8.
 17. Indja B, Woldendorp K, Valley MP, Grieve SM. Silent Brain Infarcts Following Cardiac Procedures: A Systematic Review and Meta-Analysis. *J Am Heart Assoc.* 2019;8:e010920.
 18. Ghanem A, Kocurek J, Sinning JM, Wagner M, Becker BV, Vogel M, Schröder T, Wolfgruber S, Wasa-Nicotera M, Hammerstingl C, Schwab JO, Thomas D, Werner N, Grube E, Nickenig G, Müller A. Cognitive trajectory after transcatheter aortic valve implantation. *Circ Cardiovasc Interv.* 2013;6:615-24.
 19. Lansky AJ, Brown D, Pena C, Pietras CG, Parise H, Ng VG, Meller S, Abrams KJ, Cleman M, Margolis P, Petrossian G, Brickman AM, Voros S, Moses J, Forrest JK. Neurologic Complications of Unprotected Transcatheter Aortic Valve Implantation (from the Neuro-TAVI Trial). *Am J Cardiol.* 2016;118:1519-26.
 20. Vermeer SE, Longstreth WT, Koudstaal PJ. Silent brain infarcts: a systematic review. *Lancet Neurol.* 2007;6:611-9.
 21. Schoenenberger AW, Zuber C, Moser A, Zwahlen M, Wenaweser P, Windecker S, Carrel T, Stuck AE, Stortecky S. Evolution of Cognitive Function After Transcatheter Aortic Valve Implantation. *Circ Cardiovasc Interv.* 2016;9:e003590.
 22. Lowenstern A, Hung A, Manandhar P, Wegemann ZK, Kapadia SR, Lindman BR, Goel K, Levack M, Barker CM, Reed SD, Cohen DJ, Vemulapalli S. Association of Transcatheter Aortic Valve Replacement Reimbursement, New Technology Add-on Payment, and Procedure Volumes with Embolic Protection Device Use. *JAMA Cardiol.* 2022;7:945-52.
 23. Haussig S, Mangner N, Dwyer MG, Lehmkuhl L, Lücke C, Woitek F, Holzhey DM, Mohr FW, Gutberlet M, Zivadinov R, Schuler G, Linke A. Effect of a Cerebral Protection Device on Brain Lesions Following Transcatheter Aortic Valve Implantation in Patients With Severe Aortic Stenosis: The CLEAN-TAVI Randomized Clinical Trial. *JAMA.* 2016;316:592-601.
 24. Lansky AJ, Makkar R, Nazif T, Messé S, Forrest J, Sharma R, Schofer J, Linke A, Brown D, Dhoble A, Horwitz P, Zang M, DeMarco F, Rajagopal V, Dwyer MG, Zivadinov R, Stella P, Rovin J, Parise H, Kodali S, Baumbach A, Moses J. A randomized evaluation of the TriGuard™ HDH cerebral embolic protection device to Reduce the Impact of Cerebral Embolic Lesions after TransCatheter Aortic Valve Implantation: the REFLECT I trial. *Eur Heart J.* 2021;42:2670-9.
 25. Nazif TM, Moses J, Sharma R, Dhoble A, Rovin J, Brown D, Horwitz P, Makkar R, Stoler R, Forrest J, Messé S, Dickerman S, Brennan J, Zivadinov R, Dwyer MG, Lansky AJ; REFLECT II Trial Investigators. Randomized Evaluation of TriGuard 3 Cerebral Embolic Protection After Transcatheter Aortic Valve Replacement: REFLECT II. *JACC Cardiovasc Interv.* 2021;14:515-27.
 26. Kapadia SR, Kodali S, Makkar R, Mehran R, Lazar RM, Zivadinov R, Dwyer MG, Jilalawi H, Virmani R, Anwaruddin S, Thourani VH, Nazif T, Mangner N, Woitek F, Krishnaswamy A, Mick S, Chakravarty T, Nakamura M, McCabe JM, Satler L, Zajarias A, Szeto WY, Svensson L, Alu MC, White RM, Kraemer C, Parhizgar A, Leon MB, Linke A; SENTINEL Trial Investigators. Protection Against Cerebral Embolism During Transcatheter Aortic Valve Replacement. *J Am Coll Cardiol.* 2017;69:367-77.
 27. Isogai T, Vanguru HR, Krishnaswamy A, Agrawal A, Spilias N, Shekhar S, Saad AM, Verma BR, Puri R, Reed GW, Popović ZB, Unai S, Yun JJ, Uchino K, Kapadia SR. Feasibility of Sentinel Cerebral Embolic Protection Device Deployment During Transfemoral Transcatheter Aortic Valve Replacement. *Am J Cardiol.* 2022;184:157-9.
 28. Isogai T, Bansal A, Vanguru HR, Agrawal A, Shekhar S, Puri R, Reed GW, Krishnaswamy A, Uchino K, Kapadia SR. Cerebral Embolic Protection and Stroke-Related Mortality Following Transcatheter Aortic Valve Replacement. *JACC Cardiovasc Interv.* 2022;15:569-71.
 29. Van Mieghem NM, van Gils L, Ahmad H, van Kesteren F, van der Werf HW, Brueren G, Storm M, Lenzen M, Daemen J, van den Heuvel AF, Tonino P, Baan J, Koudstaal PJ, Schipper ME, van der Lugt A, de Jaegere PP. Filter-based cerebral embolic protection with transcatheter aortic valve implantation: the randomised MISTRAL-C trial. *EuroIntervention.* 2016;12:499-507.
 30. Lansky AJ, Messé SR, Brickman AM, Dwyer M, Bart van der Worp H, Lazar RM, Pietras CG, Abrams KJ, McFadden E, Petersen NH, Browndyke J, Prendergast B, Ng VG, Cutlip DE, Kapadia S, Krucoff MW, Linke A, Moy CS, Schofer J, van Es GA, Virmani R, Popma J, Parides MK, Kodali S, Bilello M, Zivadinov R, Akar J, Furie KL, Gress D, Voros S, Moses J, Greer D, Forrest JK, Holmes D, Kappetein AP, Mack M, Baumbach A. Proposed Standardized Neurological Endpoints for Cardiovascular Clinical Trials An Academic Research Consortium Initiative. *J Am Coll Cardiol.* 2017;69:679-91.
 31. Lazar RM, Pavol MA, Bormann T, Dwyer MG, Kraemer C, White R, Zivadinov R, Wertheimer JC, Thöne-Otto A, Ravdin LD, Naugle R, Mechanic-Hamilton D, Garmoe WS, Stringer AY, Bender HA, Kapadia SR, Kodali S, Ghanem A, Linke A, Mehran R, Virmani R, Nazif T, Parhizgar A, Leon MB. Neurocognition and Cerebral Lesion Burden in High-Risk Patients Before Undergoing Transcatheter Aortic Valve Replacement: Insights From the SENTINEL Trial. *JACC Cardiovasc Interv.* 2018;11:384-92.
 32. Megaly M, Sorajja P, Cavalcante JL, Pershad A, Gössl M, Abraham B, Omer M, Elbadawi A, Garcia S. Ischemic Stroke With Cerebral Protection System During Transcatheter Aortic Valve Replacement. *JACC Cardiovasc Interv.* 2020;13:2149-55.
 33. Butala NM, Makkar R, Secemsky EA, Gallup D, Marquis-Gravel G, Kosinski AS, Vemulapalli S, Valle JA, Bradley SM, Chakravarty T, Yeh RW, Cohen DJ. Cerebral Embolic Protection and Outcomes of Transcatheter Aortic Valve Replacement: Results From the Transcatheter Valve Therapy Registry. *Circulation.* 2021;143:2229-40.
 34. Alkhouli M, Alqahtani F, Harris AH, Hohmann SF, Rihal CS. Early Experience With Cerebral Embolic Protection During Transcatheter Aortic Valve Replacement in the United States. *JAMA Intern Med.* 2020;180:783-4.
 35. Seeger J, Gonska B, Otto M, Rottbauer W, Wöhrle J. Cerebral Embolic Protection During Transcatheter Aortic Valve Replacement Significantly Reduces Death and Stroke Compared With Unprotected Procedures. *JACC Cardiovasc Interv.* 2017;10:2297-303.
 36. Seeger J, Kapadia SR, Kodali S, Linke A, Wöhrle J, Haussig S, Makkar R, Mehran R, Rottbauer W, Leon M. Rate of peri-procedural stroke observed with cerebral embolic protection during transcatheter aortic valve replacement: a patient-level propensity-matched analysis. *Eur Heart J.* 2019;40:1334-40.
 37. Kapadia SR, Makkar R, Leon M, Abdel-Wahab M, Waggoner T, Massberg S, Rottbauer W, Horr S, Sondergaard L, Karha J, Gooley R, Satler L, Stoler RC, Messé SR, Baron SJ, Seeger J, Kodali S, Krishnaswamy A, Thourani VH, Harrington K, Pocock S, Modolo R, Alocco DJ, Meredith IT, Linke A; PROTECTED TAVR Investigators. Cerebral Embolic Protection during Transcatheter Aortic-Valve Replacement. *N Engl J Med.* 2022;387:1253-63.
 38. Baumbach A, Mullen M, Brickman AM, Aggarwal SK, Pietras CG, Forrest JK, Hildick-Smith D, Meller SM, Gambone L, den Heijer P, Margolis P, Voros S, Lansky AJ. Safety and performance of a novel embolic deflection device in patients undergoing transcatheter aortic valve replacement: results from the DEFLECT I study. *EuroIntervention.* 2015;11:75-84.
 39. Samim M, van der Worp B, Agostoni P, Hendrikse J, Budde RPJ, Nijhoff F, Ramjankhan F, Doevendans PA, Stella PR. TriGuard™ HDH embolic deflection device for cerebral protection during transcatheter aortic valve replacement. *Catheter Cardiovasc Interv.* 2017;89:470-7.
 40. Lansky AJ, Schofer J, Tchetché D, Stella P, Pietras CG, Parise H, Abrams K, Forrest JK, Cleman M, Reinöhl J, Cuisset T, Blackman D, Bolotin G, Spitzer S, Kappert U, Gilard M, Modine T, Hildick-Smith D, Haude M, Margolis P, Brickman AM, Voros S, Baumbach A. A prospective randomized evaluation of the TriGuard™ HDH embolic DEFLECTION device during transcatheter aortic valve implantation: results from the DEFLECT III trial. *Eur Heart J.* 2015;36:2070-8.

41. Latib A, Mangieri A, Vezzulli P, Spagnolo P, Sardanelli F, Fellegara G, Pagnesi M, Giannini F, Falini A, Gorla R, Montorfano M, Bedogni F, Colombo A, Popma J, Merhi WM, De Marco F. First-in-Man Study Evaluating the Emblok Embolic Protection System During Transcatheter Aortic Valve Replacement. *JACC Cardiovasc Interv.* 2020;13:860-8.
42. Jagielak D, Targonski R, Frerker C, Abdel-Wahab M, Wilde J, Werner N, Lauterbach M, Leick J, Grygier M, Misterski M, Erglis A, Narbute I, Ryszard Witkowski A, Adam M, Frank D, Gatto F, Schmidt T, Lansky AJ. Safety and performance of a novel cerebral embolic protection device for transcatheter aortic valve implantation: the PROTEMBO C Trial. *EuroIntervention.* 2022;18:590-7.
43. Mylotte D, Narbute I, Neylon A, Schäfer U, Werner N, Virmani R, Kolodgie F, Zivadinov R, Erglis A. TCT-43: First-In-Human Experience of a Novel Transradial Device for Embolic Deflection During Transcatheter Aortic Valve Replacement. Paper presented at TCT 2018; 21 September 2018; San Diego, CA, USA.
44. Pasupati S. TCT CONNECT-458 Clinical Performance of a Total Embolic Protection Device: Results of the Emboliner SafePass 2 Study. *J Am Coll Cardiol.* 2020;76:B196.
45. Abizaïd A. Full-body embolic protection during TAVR: the Protect the Head-to-Head study. Paper presented at EuroPCR 2023 Session: Embolic protection, TAVI, heart failure and artificial intelligence: what's new in 2023; 19 May 2023; Paris, France.
46. Nazif TM. Performance of the New Generation Emboliner Embolic Protection Device for TAVI: the SafePass 3 Study. Paper presented at TVT 2023 Moderated Poster Session: Emerging Clinical Science: TAVR V - New TAVR Systems and AR Intervention; 09 June 2023; Phoenix, AZ, USA.
47. Komowski R, Vaknin-Assa H, Patel V. Final results of the FIH CAPTIS full-body embolic protection during TAVI. Paper presented at EuroPCR 2022 Session: PCR Innovators Day - Follow-up and technology updates; 19 May 2022; Paris, France.
48. AorticLab - FLOWer, the embolic protection device with Catch&Flow technology. <https://www.aorticlab.ch/flower/>. Last accessed 26 July 2023.
49. Sorropago A. FLOWer - The complete embolic protection device. Paper presented at EuroPCR 2023 Session: Embolic protection, TAVI, heart failure and artificial intelligence: what is new in 2023; 19 May 2023; Paris, France.
50. Linke A. Full Arch Cerebral Embolic Protection of the Brain (Point-Guard™) During Cardiovascular Procedures. Paper presented at TCT 2019; 25 September 2019; San Francisco, CA, USA.
51. Frerker C, Schlüter M, Sanchez OD, Reith S, Romero ME, Ladich E, Schröder J, Schmidt T, Kreidel F, Joner M, Virmani R, Kuck KH. Cerebral Protection During MitraClip Implantation: Initial Experience at 2 Centers. *JACC Cardiovasc Interv.* 2016;9:171-9.
52. Schmidt T, Schlüter M, Alessandrini H, Akdag O, Schewel D, Schewel J, Thielsen T, Kreidel F, Bader R, Romero M, Ladich E, Virmani R, Schäfer U, Kuck KH, Frerker C. Histology of debris captured by a cerebral protection system during transcatheter valve-in-valve implantation. *Heart.* 2016;102:1573-80.
53. Calabrò P, Gragnano F, Niccoli G, Marcucci R, Zimarino M, Spaccarotella C, Renda G, Patti G, Andò G, Moscarella E, Mancone M, Cesaro A, Giustino G, De Caterina R, Mehran R, Capodanno D, Valgimigli M, Windecker S, Dangas GD, Indolfi C, Angiolillo DJ. Antithrombotic Therapy in Patients Undergoing Transcatheter Interventions for Structural Heart Disease. *Circulation.* 2021;144:1323-43.
54. Stone GW, Lindenfeld J, Abraham WT, Kar S, Lim DS, Mishell JM, Whisenand B, Grayburn PA, Rinaldi M, Kapadia SR, Rajagopal V, Sarembock IJ, Briekie A, Marx SO, Cohen DJ, Weissman NJ, Mack MJ; COAPT Investigators. Transcatheter Mitral-Valve Repair in Patients with Heart Failure. *N Engl J Med.* 2018;379:2307-18.
55. Obadia JF, Messika-Zeitoun D, Leurent G, Iung B, Bonnet G, Piriou N, Lefèvre T, Piot C, Rouleau F, Carrié D, Nejari M, Ohlmann P, Leclercq F, Saint Etienne C, Teiger E, Leroux L, Karam N, Michel N, Gilard M, Donal E, Trochu J-N, Cormier B, Armoiry X, Boutitie F, Maucort-Boulch D, Barnel C, Samson G, Guerin P, Vahanian A, Mewton N; MITRA-FR Investigators. Percutaneous Repair or Medical Treatment for Secondary Mitral Regurgitation. *N Engl J Med.* 2018;379:2297-306.
56. Barros da Silva P, Sousa JP, Oliveiros B, Donato H, Costa M, Gonçalves L, Teixeira R. Stroke after transcatheter edge-to-edge repair of the mitral valve repair: a systematic review and meta-analysis. *EuroIntervention.* 2020;15:1401-8.
57. Blazek S, Lurz P, Mangner N, Fuernau G, Seeburger J, Luecke C, Gutberlet M, Ender J, Desch S, Eitel I, Schuler G, Thiele H. Incidence, characteristics and functional implications of cerebral embolic lesions after the MitraClip procedure. *EuroIntervention.* 2015;10:1195-203.
58. Braemswig TB, Kusserow MMD, Kruppa J, Reinthaler M, Erdur H, Fritsch M, Curio J, Alushi B, Villringer K, Galinovic I, Berger C, Leistner DM, Audebert HJ, Endres M, Landmesser U, Fiebach JB, Nolte CH, Beckhoff F, Lauten A. Cerebral embolisation during transcatheter edge-to-edge repair of the mitral valve with the MitraClip system: a prospective, observational study. *EuroIntervention.* 2022;18:e160-8.
59. Sharma SP, Cheng J, Turagam MK, Gopinathannair R, Horton R, Lam YY, Tarantini G, D'Amico G, Freixa Rofastes X, Lange M, Natale A, Lakkireddy DR. Feasibility of Left Atrial Appendage Occlusion in Left Atrial Appendage Thrombus: A Systematic Review. *JACC Clin Electrophysiol.* 2020;6:414-24.
60. Majunke N, Eplinius F, Gutberlet M, Moebius-Winkler S, Daehnert I, Grothoff M, Schürer S, Mangner N, Lurz P, Erbs S, Kirsch K, Schuler G, Sandri M. Frequency and clinical course of cerebral embolism in patients undergoing transcatheter left atrial appendage closure. *EuroIntervention.* 2017;13:124-30.
61. Laible M, Möhlenbruch M, Horstmann S, Pfaff J, Geis NA, Pleger S, Schüler S, Rizo T, Bendszus M, Veltkamp R. Peri-procedural silent cerebral infarcts after left atrial appendage occlusion. *Eur J Neurol.* 2017;24:53-7.
62. Rillig A, Bellmann B, Skurk C, Leistner DM, Haeusler KG, Lin T, Geran R, Koehler L, Guttman S, Steffens D, Kasner M, Jakob P, Tscholl V, Roser M, Lenz K, Villringer K, Park JW, Fiebach JB, Landmesser U. Left atrial appendage angiography is associated with the incidence and number of magnetic resonance imaging-detected brain lesions after percutaneous catheter-based left atrial appendage closure. *Heart Rhythm.* 2018;15:3-8.
63. Tripathi B, Arora S, Kumar V, Abdelrahman M, Lahewala S, Dave M, Shah M, Tan B, Savani S, Badheka A, Gopalan R, Shantha GPS, Viles-Gonzalez J, Deshmukh A. Temporal trends of in-hospital complications associated with catheter ablation of atrial fibrillation in the United States: An update from Nationwide Inpatient Sample database (2011-2014). *J Cardiovasc Electrophysiol.* 2018;29:715-24.
64. Calkins H, Hindricks G, Cappato R, Kim YH, Saad EB, Aguinaga L, Akar JG, Badhwar V, Brugada J, Camm J, Chen PS, Chen SA, Chong MK, Nielsen JC, Curtis AB, Davies DW, Day JD, d'Avila A, de Groot MMSN, Di Biase L, Duytschaever M, Edgerton JR, Ellenbogen KA, Ellinor PT, Ernst S, Fenelon G, Gerstenfeld EP, Haines DE, Haissaguerre M, Helm RH, Hylek E, Jackman WM, Jalife J, Kalman JM, Kautzner J, Kottkamp H, Kuck KH, Kumagai K, Lee R, Lewalter T, Lindsay BD, Macle L, Mansour M, Marchlinski FE, Michaud GF, Nakagawa H, Natale A, Nattel S, Okumura K, Packer D, Pokushalov E, Reynolds MR, Sanders P, Scanavacca M, Schilling R, Tondo C, Tsao HM, Verma A, Wilber DJ, Yamane T. 2017 HRS/EHRA/ECAS/APHS/SOLAECE expert consensus statement on catheter and surgical ablation of atrial fibrillation. *Heart Rhythm.* 2017;14:e275-444.
65. Whitman IR, Gladstone RA, Badhwar N, Hsia HH, Lee BK, Josephson SA, Meisel KM, Dillon WP, Hess CP, Gerstenfeld EP, Marcus GM. Brain Emboli After Left Ventricular Endocardial Ablation. *Circulation.* 2017;135:867-77.
66. Deneke T, Shin DI, Balta O, Bünz K, Fassbender F, Mütge A, Anders H, Horlitz M, Päsler M, Karthikapallil S, Arentz T, Beyer D, Bansmann M. Postablation asymptomatic cerebral lesions: long-term follow-up using magnetic resonance imaging. *Heart Rhythm.* 2011;8:1705-11.
67. Herrera Siklódy C, Deneke T, Hocini M, Lehrmann H, Shin DI, Miyazaki S, Henschke S, Fluegel P, Schiebeling-Römer J, Bansmann PM, Bourdias T, Doussset V, Haissaguerre M, Arentz T. Incidence of asymptomatic intracranial embolic events after pulmonary vein isolation: comparison of different atrial fibrillation ablation technologies in a multicenter study. *J Am Coll Cardiol.* 2011;58:681-8.
68. Heeger CH, Metzner A, Schlüter M, Rillig A, Mathew S, Tilz RR, Wohlmuth P, Romero ME, Virmani R, Fink T, Reissmann B, Lemes C, Maurer T, Santoro F, Schmidt T, Ghanem A, Frerker C, Kuck KH, Ouyang F. Cerebral Protection During Catheter Ablation of Ventricular Tachycardia in Patients With Ischemic Heart Disease. *J Am Heart Assoc.* 2018;7:e009005.
69. Zachariah D, Limite LR, Mazzone P, Marzi A, Radinovic A, Baratto F, Italia L, Ancona F, Paglino G, Della Bella P. Use of Cerebral Protection Device in Patients Undergoing Ventricular Tachycardia Catheter Ablation. *JACC Clin Electrophysiol.* 2022;8:528-30.
70. Gutsche JT, Cheung AT, McGarvey ML, Moser WG, Szeto W, Carpenter JP, Fairman RM, Pochettino A, Bavaria JE. Risk factors for perioperative stroke after thoracic endovascular aortic repair. *Ann Thorac Surg.* 2007;84:1195-200.
71. Melissano G, Tshomba Y, Bertoglio L, Rinaldi E, Chiesa R. Analysis of stroke after TEVAR involving the aortic arch. *Eur J Vasc Endovasc Surg.* 2012;43:269-75.
72. Bismuth J, Garami Z, Anaya-Ayala JE, Naoum JJ, el Sayed HF, Peden EK, Lumsden AB, Davies MG. Transcranial Doppler findings during thoracic endovascular aortic repair. *J Vasc Surg.* 2011;54:364-9.
73. Perera AH, Rudarakanchana N, Monzon L, Bicknell CD, Modarai B, Kirmi O, Athanasiou T, Hamady M, Gibbs RG. Cerebral embolization, silent cerebral infarction and neurocognitive decline after thoracic endovascular aortic repair. *Br J Surg.* 2018;105:366-78.
74. Ryomoto M, Tanaka H, Kajiyama T, Mitsuno M, Yamamura M, Fukui S, Miyamoto Y. Endovascular Aortic Arch Repair with Mini-Cardiopulmonary Bypass to Prevent Stroke. *Ann Vasc Surg.* 2016;36:320-4.
75. Spear R, Haulon S, Ohki T, Tsilimiparis N, Kanaoka Y, Milne CPE, Debus S, Takizawa R, Kölbel T. Editor's Choice - Subsequent Results for Arch Aneurysm Repair with Inner Branched Endografts. *Eur J Vasc Endovasc Surg.* 2016;51:380-5.

76. Perera AH, Riga CV, Monzon L, Gibbs RG, Bicknell CD, Hamady M. Robotic Arch Catheter Placement Reduces Cerebral Embolization During Thoracic Endovascular Aortic Repair (TEVAR). *Eur J Vasc Endovasc Surg.* 2017;53:362-9.
77. Kölbl T, Rohlfis F, Wipper S, Carpenter SW, Debus ES, Tsilimparis N. Carbon Dioxide Flushing Technique to Prevent Cerebral Arterial Air Embolism and Stroke During TEVAR. *J Endovasc Ther.* 2016;23:393-5.
78. Kossar AP, Takayama H, Patel V, George I. Novel Implementation of a Cerebral Protection System During Ascending Thoracic Endovascular Aortic Repair (TEVAR). *Semin Thorac Cardiovasc Surg.* 2019;31:218-21.
79. Grover G, Perera AH, Hamady M, Rudarakanchana N, Barras CD, Singh A, Davies AH, Gibbs R. Cerebral embolic protection in thoracic endovascular aortic repair. *J Vasc Surg.* 2018;68:1656-66.
80. Shah AS, Akhmerov A, Gupta N, Chakravarty T, Makkar RR, Azizzadeh A. Use of a Dual-Filter Cerebral Embolic Protection Device in Thoracic Endovascular Aortic Repair. *Ann Vasc Surg.* 2020;65:54.e1-e4.
81. Kahlert P, Eggebrecht H, János RA, Hildebrandt HA, Plicht B, Tsagakis K, Moeninghoff C, Nensa F, Mummel P, Heusch G, Jakob HG, Forsting M, Erbel R, Schlamann M. Silent cerebral ischemia after thoracic endovascular aortic repair: a neuroimaging study. *Ann Thorac Surg.* 2014;98:53-8.
82. Reddy VY, Neuzil P, de Potter T, van der Heyden J, Tromp SC, Rensing B, Jiresova E, Dujka L, Lekesova V. Permanent Percutaneous Carotid Artery Filter to Prevent Stroke in Atrial Fibrillation Patients: The CAPTURE Trial. *J Am Coll Cardiol.* 2019;74:829-39.
83. Van Gils L, Kroon H, Daemen J, Ren C, Maugenes AM, Schipper M, De Jaegere PP, Van Mieghem NM. Complete filter-based cerebral embolic protection with transcatheter aortic valve replacement. *Catheter Cardiovasc Interv.* 2018;91:790-7.
84. Bogren HG, Buonocore MH, Gu WZ. Carotid and vertebral artery blood flow in left- and right-handed healthy subjects measured with MR velocity mapping. *J Magn Reson Imaging.* 1994;4:37-42.
85. Fanning JP, Wesley AJ, Walters DL, Wong AA, Barnett AG, Strugnell WE, Platts DG, Fraser JF. Topographical distribution of perioperative cerebral infarction associated with transcatheter aortic valve implantation. *Am Heart J.* 2018;197:113-23.
86. Astarci P, Glineur D, Kefer J, D'Hoore W, Renkin J, Vanovershelde JL, El Khoury G, Grandin C. Magnetic resonance imaging evaluation of cerebral embolization during percutaneous aortic valve implantation: comparison of transfemoral and trans-apical approaches using Edwards Sapiens valve. *Eur J Cardiothorac Surg.* 2011;40:475-9.
87. Abdel-Wahab M, Richter I, Taramasso M, Unbehaun A, Rudolph T, Ribichini FL, Binder R, Schofer J, Mangner N, Dambink JH, Trejo-Velasco B, Thiele H, Kitamura M, Lanz J. Procedural and one-year outcomes of the BASILICA technique in Europe: the multicentre EURO-BASILICA registry. *EuroIntervention.* 2023;19:e432-41.
88. Palmerini T, Saia F, Kim WK, Renker M, Iadanza A, Fineschi M, Bruno AG, Ghetti G, Vanhaverbeke M, Søndergaard L, De Backer O, Romagnoli E, Burzotta F, Trani C, Adrighem R, Van Mieghem NM, Nardi E, Chietera F, Orzalkiewicz M, Tomii D, Pilgrim T, Aranzulla TC, Musumeci G, Adam M, Meertens MM, Taglieri N, Marzocchi C, Alvarez Covarrubias HA, Jonek M, Nardi G, Di Muro FM, Di Mario C, Loretz L, Toggweiler S, Gallitto E, Gargiulo M, Testa L, Bedogni F, Berti S, Ancona MB, Montorfano M, Leone A, Savini C, Pacini D, Gmeiner J, Braun D, Nerla R, Castriota F, De Carlo M, Petronio AS, Barbanti M, Costa G, Tamburino C, Leone PP, Reimers B, Stefanini G, Sudo M, Nickenig G, Piva T, Scotti A, Latib A, Vercellino M, Porto I, Codner P, Kornowski R, Bartorelli AL, Tarantini G, Fraccaro C, Abdel-Wahab M, Grube E, Galíe N, Stone GW. Vascular Access in Patients With Peripheral Arterial Disease Undergoing TAVR: The Hostile Registry. *JACC Cardiovasc Interv.* 2023;16:396-411.
89. Brown JM, O'Brien SM, Wu C, Sikora JA, Griffith BP, Gammie JS. Isolated aortic valve replacement in North America comprising 108,687 patients in 10 years: Changes in risks, valve types, and outcomes in the Society of Thoracic Surgeons National Database. *J Thorac Cardiovasc Surg.* 2009;137:82-90.
90. Messé SR, Acker MA, Kasner SE, Fanning M, Giovannetti T, Ratcliffe SJ, Bilello M, Szeto WY, Bavaria JE, Hargrove WC 3rd, Mohler ER 3rd, Floyd TF; Determining Neurologic Outcomes from Valve Operations (DeNOVO) Investigators. Stroke after aortic valve surgery: results from a prospective cohort. *Circulation.* 2014;129:2253-61.
91. Hamm CW, Möllmann H, Holzhey D, Beckmann A, Veit C, Figulla HR, Cremer J, Kuck KH, Lange R, Zahn R, Sack S, Schuler G, Walther T, Beyersdorf F, Böhm M, Heusch G, Funkat AK, Meinerz T, Neumann T, Papoutsis K, Schneider S, Welz A, Mohr FW; GARY-Executive Board. The German Aortic Valve Registry (GARY): in-hospital outcome. *Eur Heart J.* 2014;35:1588-98.
92. Kapadia SR, Huded CP, Kodali SK, Svensson LG, Tuzcu EM, Baron SJ, Cohen DJ, Miller DC, Thourani VH, Herrmann HC, Mack MJ, Szerlip M, Makkar RR, Webb JG, Smith CR, Rajeswaran J, Blackstone EH, Leon MB; PARTNER Trial Investigators. Stroke After Surgical Versus Transfemoral Transcatheter Aortic Valve Replacement in the PARTNER Trial. *J Am Coll Cardiol.* 2018;72:2415-26.
93. Mack MJ, Acker MA, Gelijns AC, Overbey JR, Parides MK, Browndyke JN, Groh MA, Moskowitz AJ, Jeffries NO, Ailawadi G, Thourani VH, Moquete EG, Iribarne A, Voisine P, Perrault LP, Bowdish ME, Bilello M, Davatzikos C, Mangusan RF, Winkle RA, Smith PK, Michler RE, Miller MA, O'Sullivan KL, Taddei-Peters WC, Rose EA, Weisel RD, Furie KL, Bagiella E, Moy CS, O'Gara PT, Messé SR; Cardiothoracic Surgical Trials Network (CTSN). Effect of Cerebral Embolic Protection Devices on CNS Infarction in Surgical Aortic Valve Replacement: A Randomized Clinical Trial. *JAMA.* 2017;318:536-47.
94. Kharbada RK, Perkins AD, Kennedy J, Banning AP, Baumbach A, Blackman DJ, Dodd M, Evans R, Hildick-Smith D, Jamal Z, Ludman P, Palmer S, Stables R, Clayton T. Routine cerebral embolic protection in transcatheter aortic valve implantation: rationale and design of the randomised British Heart Foundation PROTECT-TAVI trial. *EuroIntervention.* 2023;18:1428-35.
95. Kharbada R, Kapadia S. SENTINEL PROTECTION: A Global Prospective Meta-Analysis of the PROTECTED TAVR and BHF PROTECT-TAVI Studies. PROSPERO 2022 CRD42022324160. https://www.crd.york.ac.uk/prospero/display_record.php?ID=CRD42022324160. Last accessed 26 July 2023.
96. Rodés-Cabau J, Kahlert P, Neumann FJ, Schymik G, Webb JG, Amareno P, Brodt T, Garami Z, Gerosa G, Lefèvre T, Plicht B, Pocock SJ, Schlamann M, Thomas M, Diamond B, Merioua I, Beyersdorf F, Vahanian A. Feasibility and exploratory efficacy evaluation of the Embrella Embolic Deflector system for the prevention of cerebral emboli in patients undergoing transcatheter aortic valve replacement: the PROTAVI-C pilot study. *JACC Cardiovasc Interv.* 2014;7:1146-55.
97. Van Mieghem NM, Schipper ME, Ladich E, Faqiri E, van der Boon R, Randjari A, Schultz C, Moelker A, van Geuns RJ, Otsuka F, Serruys PW, Virmani R, de Jaegere PP. Histopathology of embolic debris captured during transcatheter aortic valve replacement. *Circulation.* 2013;127:2194-201.
98. Van Mieghem NM, El Faquir N, Rahhab Z, Rodríguez-Olivares R, Wilschut J, Ouhlous M, Galema TW, Geleijnse ML, Kappetein AP, Schipper ME, de Jaegere PP. Incidence and predictors of debris embolizing to the brain during transcatheter aortic valve implantation. *JACC Cardiovasc Interv.* 2015;8:718-24.
99. Schmidt T, Akdag O, Wohlmuth P, Thielsen T, Schewel D, Schewel J, Alessandrini H, Kreidel F, Bader R, Romero M, Ladich E, Virmani R, Schäfer U, Kuck KH, Frerker C. Histological Findings and Predictors of Cerebral Debris From Transcatheter Aortic Valve Replacement: The ALSTER Experience. *J Am Heart Assoc.* 2016;5:e004399.
100. Kapadia S, Kodali S, Makkar R, Mehran R, Lazar RM, Zivadinov R, Dwyer MG, Jilalawi H, Virmani R, Anwaruddin S, Thourani VH, Nazif T, Mangner N, Woitek F, Krishnaswamy A, Mick S, Chakravarty T, Nakamura M, McCabe JM, Satler L, Zajarias A, Szeto WY, Svensson L, Alu MC, White RM, Kraemer C, Parhizgar A, Leon MB, Linke A; SENTINEL Trial Investigators. Protection Against Cerebral Embolism During Transcatheter Aortic Valve Replacement. *J Am Coll Cardiol.* 2017;69:367-77.
101. Schmidt T, Leon MB, Mehran R, Kuck KH, Alu MC, Braumann RE, Kodali S, Kapadia SR, Linke A, Makkar R, Naber C, Romero ME, Virmani R, Frerker C. Debris Heterogeneity Across Different Valve Types Captured by a Cerebral Protection System During Transcatheter Aortic Valve Replacement. *JACC Cardiovasc Interv.* 2018;11:1262-73.
102. Seeger J, Virmani R, Romero M, Gonska B, Rottbauer W, Wöhrle J. Significant Differences in Debris Captured by the Sentinel Dual-Filter Cerebral Embolic Protection During Transcatheter Aortic Valve Replacement Among Different Valve Types. *JACC Cardiovasc Interv.* 2018;11:1683-93.
103. Kroon H, von der Thusen JH, Ziviello F, van Wiechen M, Ooms JFW, Kardys I, Schipper M, van Gils L, Daemen J, de Jaegere P, Van Mieghem NM. Heterogeneity of debris captured by cerebral embolic protection filters during TAVI. *EuroIntervention.* 2021;16:1141-7.
104. Donà C, Koschutnik M, Nitsche C, Winter MP, Seidl V, Siller-Matula J, Mach M, Andreas M, Bartko P, Kammerlander AA, Goliash G, Lang I, Hengstenberg C, Mascherbauer J. Cerebral Protection in TAVR-Can We Do Without? A Real-World All-Come Intention-to-Treat Study-Impact on Stroke Rate, Length of Hospital Stay, and Twelve-Month Mortality. *J Pers Med.* 2022;12:320.
105. Kawakami R, Gada H, Rinaldi MJ, Nazif TM, Leon MB, Kapadia S, Krishnaswamy A, Sakamoto A, Sato Y, Mori M, Kawai K, Cornelissen A, Park JE, Ghosh SKB, Abebe BG, Romero M, Virmani R, Finn AV. Characterization of Cerebral Embolic Capture Using the SENTINEL Device During Transcatheter Aortic Valve Implantation in Low to Intermediate-Risk Patients: The SENTINEL-LIR Study. *Circ Cardiovasc Interv.* 2022;15:e011358.
106. Krawczyk-Ożóg A, Siudak Z, Sorysz D, Holda MK, Plotek A, Dziewierz A, Gackowski A, Dudek D. Comparison of clinical and echocardiographic outcomes and quality of life in patients with severe mitral regurgitation treated by MitraClip implantation or treated conservatively. *Postępy Kardiologii Interwencyjnej.* 2018;14:291-8.

107. Webb J, Hensey M, Fam N, Rodés-Cabau J, Daniels D, Smith R, Szeto W, Boone R, Ye J, Moss R, Peterson M, Ong G, Paradis JM, Dagenais F, Wintzer-Wehekind J, Shafi B, Nair D, Szerlip M, Grayburn P, Silvestry F, Koulogiannis K, Hermiller J, Guyton R, Herrmann H. Transcatheter Mitral Valve Replacement With the Transseptal EVOQUE System. *JACC Cardiovasc Interv.* 2020;13:2418-26.
108. Bapat V, Rajagopal V, Meduri C, Farivar RS, Walton A, Duffy SJ, Gooley R, Almeida A, Reardon MJ, Kleiman NS, Spargias K, Pattakos S, Ng MK, Wilson M, Adams DH, Leon M, Mack MJ, Chenoweth S, Sorajja P; Intrepid Global Pilot Study Investigators. Early Experience With New Transcatheter Mitral Valve Replacement. *J Am Coll Cardiol.* 2018;71:12-21.
109. Zahr F, Song HK, Chadderdon SM, Gada H, Mumtaz M, Byrne T, Kirshner M, Bajwa T, Weiss E, Kodali S, George I, Heiser J, Merhi WM, Thaden JJ, Zhang A, Lim DS, Reardon MJ, Adams DH, Mack MJ, Leon MB. 30-Day Outcomes Following Transfemoral Transseptal Transcatheter Mitral Valve Replacement: Intrepid TMVR Early Feasibility Study Results. *JACC Cardiovasc Interv.* 2022;15:80-9.
110. Sorajja P, Moat N, Badhwar V, Walters D, Paone G, Bethea B, Bae R, Dahle G, Mumtaz M, Grayburn P, Kapadia S, Babaliaros V, Guerrero M, Satler L, Thourani V, Bedogni F, Rizik D, Denti P, Dumonteil N, Modine T, Sinhal A, Chuang ML, Popma JJ, Blanke P, Leipsic J, Muller D. Initial Feasibility Study of a New Transcatheter Mitral Prosthesis: The First 100 Patients. *J Am Coll Cardiol.* 2019;73:1250-60.
111. Eleid MF, Whisenant BK, Cabalka AK, Williams MR, Nejjarri M, Attias D, Fam N, Amoroso N, Foley TA, Pollak PM, Alli OO, Pislaru SV, Said SM, Dearani JA, Rihal CS. Early Outcomes of Percutaneous Transvenous Transseptal Transcatheter Valve Implantation in Failed Bioprosthetic Mitral Valves, Ring Annuloplasty, and Severe Mitral Annular Calcification. *JACC Cardiovasc Interv.* 2017;10:1932-42.
112. Nickenig G, Schueler R, Dager A, Martinez Clark P, Abizaid A, Siminiak T, Buszman P, Demkow M, Ebner A, Asch FM, Hammerstingl C. Treatment of Chronic Functional Mitral Valve Regurgitation With a Percutaneous Annuloplasty System. *J Am Coll Cardiol.* 2016;67:2927-36.
113. Messika-Zeitoun D, Nickenig G, Latib A, Kuck KH, Baldus S, Schueler R, La Canna G, Agricola E, Kreidel F, Huntgeburth M, Zuber M, Verta P, Grayburn P, Vahanian A, Maisano F. Transcatheter mitral valve repair for functional mitral regurgitation using the Cardioband system: 1 year outcomes. *Eur Heart J.* 2019;40:466-72.
114. Jorde U. AccuCinch: Outcomes of Transcatheter LV Volume Reduction in HFrEF With a Transcatheter Ventricular Restoration System. Paper presented at TCT 2021; 06 November 2021; Orlando, FL, USA.
115. Holmes DR, Reddy VY, Turi ZG, Doshi SK, Sievert H, Buchbinder M, Mullin CM, Sick P; PROTECT AF Investigators. Percutaneous closure of the left atrial appendage versus warfarin therapy for prevention of stroke in patients with atrial fibrillation: a randomised non-inferiority trial. *Lancet.* 2009;374:534-42.
116. Holmes DR Jr, Kar S, Price MJ, Whisenant B, Sievert H, Doshi SK, Huber K, Reddy VY. Prospective randomized evaluation of the Watchman Left Atrial Appendage Closure device in patients with atrial fibrillation versus long-term warfarin therapy: the PREVAIL trial. *J Am Coll Cardiol.* 2014;64:1-12.
117. Freeman JV, Varosy P, Price MJ, Slotwiner D, Kusumoto FM, Rammohan C, Kavinsky CJ, Turi ZG, Akar J, Koutras C, Curtis JP, Masoudi FA. The NCDR Left Atrial Appendage Occlusion Registry. *J Am Coll Cardiol.* 2020;75:1503-18.
118. Landmesser U, Schmidt B, Nielsen-Kudsk JE, Lam SCC, Park JW, Tarantini G, Cruz-Gonzalez I, Geist V, Della Bella P, Colombo A, Zeus T, Omran H, Piorowski C, Lund J, Tondo C, Hildick-Smith D. Left atrial appendage occlusion with the AMPLATZER Amulet device: periprocedural and early clinical/echocardiographic data from a global prospective observational study. *EuroIntervention.* 2017;13: 867-76.
119. Tzikas A, Shakir S, Gafoor S, Omran H, Berti S, Santoro G, Kefer J, Landmesser U, Nielsen-Kudsk JE, Cruz-Gonzalez I, Sievert H, Tichelbäcker T, Kanagaratnam P, Nietlispach F, Aminian A, Kasch F, Freixa X, Danna P, Rezzaghi M, Vermeersch P, Stock F, Stolcova M, Costa M, Ibrahim R, Schillinger W, Meier B, Park JW. Left atrial appendage occlusion for stroke prevention in atrial fibrillation: multicentre experience with the AMPLATZER Cardiac Plug. *EuroIntervention.* 2016;11:1170-9.
120. Hildick-Smith D, Landmesser U, Camm AJ, Diener HC, Paul V, Schmidt B, Settergren M, Teiger E, Nielsen-Kudsk JE, Tondo C. Left atrial appendage occlusion with the Amplatzer™ Amulet™ device: full results of the prospective global observational study. *Eur Heart J.* 2020;41:2894-901.
121. Ali M, Rigopoulos AG, Mammadov M, Torkey A, Auer A, Matiakis M, Abate E, Bakogiannis C, Tzikas S, Bigalke B, Sedding D, Noutsias M. Systematic review on left atrial appendage closure with the LAmbre device in patients with non-valvular atrial fibrillation. *BMC Cardiovasc Disord.* 2020;20:78.
122. Itoh S, Suda K, Kishimoto S, Nishino H, Kudo Y, Iemura M, Teramachi Y, Matsuishi T, Yasunaga H. Microembolic signals measured by transcranial Doppler during transcatheter closure of atrial septal defect using the Amplatzer septal occluder. *Cardiol Young.* 2011;21:182-6.
123. Oktay Tureli H, Ungan I, Tureli D, Demir B, Pirhan O, Bayrak HI, Caglar IM, Karakaya O, Inci E. Risk of cerebral embolism after interventional closure of symptomatic patent foramen ovale or atrial septal defect: a diffusion-weighted MRI and neuron-specific enolase-based study. *J Invasive Cardiol.* 2013;25:519-24.
124. Dorenbeck U, Simon B, Skowasch D, Stüsser C, Gockel A, Schild HH, Urbach H, Bauriedel G. Cerebral embolism with interventional closure of symptomatic patent foramen ovale: an MRI-based study using diffusion-weighted imaging. *Eur J Neurol.* 2007;14:451-4.
125. Patel D, Bailey SM, Furlan AJ, Ching M, Zachaib J, Di Biase L, Mohanty P, Horton RP, Burkhardt JD, Sanchez JE, Zagrodzky JD, Gallinhouse GJ, Schweikert R, Saliba W, Natale A. Long-term functional and neurocognitive recovery in patients who had an acute cerebrovascular event secondary to catheter ablation for atrial fibrillation. *J Cardiovasc Electrophysiol.* 2010;21:412-7.
126. Kosiuk J, Kornej J, Bollmann A, Piorowski C, Myrda K, Arya A, Sommer P, Richter S, Rolf S, Husser D, Gaspar T, Lip GY, Hindricks G. Early cerebral thromboembolic complications after radiofrequency catheter ablation of atrial fibrillation: incidence, characteristics, and risk factors. *Heart Rhythm.* 2014;11:1934-40.
127. Bertaglia E, Stabile G, Pappone A, Themistoclakis S, Tondo C, De Sanctis V, Soldati E, Tritto M, Solimene F, Grimaldi M, Zoppo F, Pandozi C, Augello G, Calò L, Pappone C. Updated national multicenter registry on procedural safety of catheter ablation for atrial fibrillation. *J Cardiovasc Electrophysiol.* 2013;24:1069-74.
128. Bohnen M, Stevenson WG, Tedrow UB, Michaud GF, John RM, Epstein LM, Albert CM, Koplan BA. Incidence and predictors of major complications from contemporary catheter ablation to treat cardiac arrhythmias. *Heart Rhythm.* 2011;8: 1661-6.
129. Scherr D, Sharma K, Dalal D, Spragg D, Chilukuri K, Cheng A, Dong J, Henrikson CA, Nazarian S, Berger RD, Calkins H, Marine JE. Incidence and predictors of periprocedural cerebrovascular accident in patients undergoing catheter ablation of atrial fibrillation. *J Cardiovasc Electrophysiol.* 2009;20:1357-63.
130. Rao HB, Yu R, Chitnis N, DO D, Boyle NG, Shivkumar K, Bradfield JS. Ventricular Tachycardia Ablation in the Presence of Left Ventricular Thrombus: Safety and Efficacy. *J Cardiovasc Electrophysiol.* 2016;27:453-9.
131. Haeusler KG, Koch L, Herm J, Kopp UA, Heuschmann PU, Endres M, Schultheiss HP, Schirdewan A, Fiebich JB. 3 Tesla MRI-detected brain lesions after pulmonary vein isolation for atrial fibrillation: results of the MACPAF study. *J Cardiovasc Electrophysiol.* 2013;24:14-21.
132. Gaita F, Leclercq JF, Schumacher B, Scaglione M, Toso E, Halimi F, Schade A, Froehner S, Ziegler V, Sergi D, Cesarani F, Blandino A. Incidence of silent cerebral thromboembolic lesions after atrial fibrillation ablation may change according to technology used: comparison of irrigated radiofrequency, multipolar nonirrigated catheter and cryoballoon. *J Cardiovasc Electrophysiol.* 2011;22:961-8.
133. Bismuth J, Garami Z, Anaya-Ayala JE, Naoum JJ, El Sayed HF, Peden EK, Lumsden AB, Davies MG. Transcranial Doppler findings during thoracic endovascular aortic repair. *J Vasc Surg.* 2011;54:364-9.
134. Murphy EH, Stanley GA, Ilves M, Knowles M, Dimairo JM, Jessen ME, Arko FR. Thoracic endovascular repair (TEVAR) in the management of aortic arch pathology. *Ann Vasc Surg.* 2012;26:55-66.
135. Ullery BW, McGarvey M, Cheung AT, Fairman RM, Jackson BM, Woo EY, Desai ND, Wang GJ. Vascular distribution of stroke and its relationship to perioperative mortality and neurologic outcome after thoracic endovascular aortic repair. *J Vasc Surg.* 2012;56:1510-7.